

# Histomorphometric analysis of the reticulum of the sheep during development

A. Franco<sup>1</sup>, A. Robina<sup>1</sup>, S. Regodón<sup>1</sup>, J.M. Vivo<sup>1</sup>, A.J. Masot<sup>2</sup> and E. Redondo<sup>2</sup>

<sup>1</sup>Department of Anatomy and Embryology and <sup>2</sup>Department of Histology and Pathology, Faculty of Veterinary Sciences, Cáceres, Spain

**Summary.** Histomorphometric and scanning electron microscopic analysis were performed on 74 embryos and foetuses and on 20 sheep (early post-natal to adult age).

Histodifferentiation of the reticulum took place at 33 days of foetal life. Reticular ribs were observed as evaginations of the epithelial stratum germinativum at 64 days.

Neutral mucopolysaccharides first appeared in epithelial cells at 46 foetal days, thereafter to decrease gradually in number, subsequently stabilising in postnatal life. Acid mucopolysaccharides, mucins and mucoid compounds were not detected.

Growth curves and formulae were constructed for each tissue layer. Initial test involved multiplicative ( $y=ax^b$ ), linear ( $y=a+bx$ ) and polynomial model ( $y=a+bx+cx^2+dx^3$ ).

**Key words:** Reticulum, Sheep, Development

## Introduction

The notable ability of ruminants to convert fibrous foods into products of great nutritive value has focused scientific interest on the structure and function of the digestive tract in these animals. A great deal of research has been carried out into the histological structure of the reticulum during postnatal development (Trautman and Fiebiger, 1957; Scott and Gardner, 1973; McGavin and Morrill, 1973), though relatively few studies deal specifically with the prenatal development of the compartmentalized stomach (Warner, 1958; Fath El-Bab et al., 1983; Amasaki and Daigo, 1987; Franco et al., 1992).

The purpose of the present study was to trace the histomorphogenic development of the reticulum from the early stages of foetal life until adult age, and to assess the histochemical behaviour of the epithelium, with particular reference to the secretion of nitrogenated

polysaccharides. Scanning electron microscopy was used to make comparative studies of the reticular mucosa at birth and at adult age.

## Materials and methods

### Animals

Sheep-embryos and foetuses (n=74) and sheep from early postnatal to adult age (n=20) were studied. Specimens from these sheep were arranged in 9 age groups, with reference to the most relevant histomorphogenic characteristics (Table 1). To obtain embryos and foetuses at different stages of development, caesarian sections were performed after synchronisation of oestrus, effect of sire and flushing. Fluogesterone acetate was used in the hormonal techniques fourteen days before introduction of males. In this moment, 600 UI of PMSG were inoculated. From day 26 and the following ones to the introduction of males, caesarian section was performed. The animals were tranquilized with an intramuscular injection of 0.5 mg/100 Kg of propionyl phenothiazin. The anaesthesia was induced by an intravenous injection of sodium thiopental (4g in 20% aqueous solution).

Once they had been separated from the maternal linking, they were sacrificed by umbilical administration of barbituric. Two transversal cuts, one of them in the caudal angle of the scapula, and the other one cranial to the coxal bone were made when the foetuses were small. The central section from the three made was selected and fixed in 10% formol.

Square samples measuring 1.5 x 0.5 cm were taken from the medial region of the reticulum of each animal. Tissues for histological study were processed by routine paraffin-embedding methods, and sections 5 µm thick were cut and stained with haematoxylin-eosin (H&E), Masson's trichrome (TM) and Van Giesson (VG) for routine morphological studies. Samples were also stained with PAS (pH 7.2) and PAS alcian blue (PAS-AB, pH 4.2) for specific differentiation of neutral and acid mucopolysaccharides. Specific staining for

## Development of sheep reticulum

**Table 1.** Experimental design giving details of age, crown-to-rump (C-R), and number of specimens per group from which the study of reticulum was completed.

GROUP	AGE (days)	C-R LENGTH (cm)	NUMBER OF SPECIMENS
1	23-29	0.4-1.9	9
2	30-32	2.0-2.5	6
3	33-38	2.6-3.6	7
4	39-52	4.0-8.0	11
5	53-79	8.5-19.0	13
6	81-112	20.0-31.5	10
7	113-118	32.0-36.0	8
8	120-150	37.0-40.0	10
9	postnatal life	2 days-2 years	20

mucoproteins and glucoproteins was performed using Mayer's mucicarmine.

### Morphometric analysis

Specimens for morphometric analysis were embedded in paraffin, stained with H&E and viewed through a microscope equipped with a videocamera. The image was reflected onto the screen of a semi-automatic image analyzer (Vid III). Variables studied were: height of various tissue strata (epithelium, lamina propria and submucosa, tunica muscularis, and serosa); and total wall thickness. Five specimens selected from each group, and 30 measurements were made for each tissue stratum. Using the same screen image, a reference area, 10 x 10  $\mu\text{m}$ , was marked off; the portion of this area occupied by a positive histochemical reaction was measured.

### Measurement of the layers

Tissue growth models were created, using a personal computer and a statistics programme (Statgraphics V 5.0, 1990, USA). The model used in each case depended on the form of the real growth curve. Initial test involved multiplicative ( $y=axb$ ) and exponential ( $y=EXP(a+bx)$ ) models. A criterium for the models was a correlation coefficient ( $r^2 > 0.70$ ). A polynomial model ( $y=a+bx+c^2+dx^3+ex^4$ ) was selected in cases where the process dynamics yielded a sigmoid pattern. When the real model obtained was not a good adjuster, either

because of a low  $r^2$  ( $r^2 < 0.70$ ) or because of its deviation from the real kinetics on some steps, step adjustment was made. The initial step by one of the model explained and the final step by an easy linear model:  $y=a+bx$ , or a new multiplicative or exponential equation with a different pendent. In all cases, embryo body length (crown to rump (C-R) in cm) was used as the independent variable; the thickness, in micrometers of each tissue stratum served as the dependent variable.

### Scanning electron microscopy (SEM)

Tissue specimen from SEM were taken from 2-day-old lambs ( $n=10$ ) and from adult sheep (two years old) ( $n=10$ ) to assess the influence of milk and fibrous diets on structural modifications of the reticulum. Specimens were fixed in 2.5% glutaraldehyde, dehydrated through graded ethanols and amyl acetate and dried in a critical-point dryer. Sections were attached to metal stubs with carbon and gold and examined at different tilt angles.

## Results

### Reticular histomorphogenesis

#### Gestation days 23-29 (0.4-1.9 cm C-R)

At 26 days of foetal life, the primitive stomach appeared as a fusiform tube enclosing a single cavity with a thin, though irregular wall ( $229 \pm 13 \mu\text{m}$ ). It consisted of two distinct layers (Fig. 1), one internal (1) (epithelium) and the other external (2) (pluripotential blastemic tissue).

The epithelium (1) ( $54.1 \pm 8 \mu\text{m}$ ) was pseudo-stratified, and without secretory capacity. It was formed by cylindrical cells whose spherical nuclei were located in the middle and apical thirds of the epithelium, leaving a peripheral band of light cytoplasm.

The subepithelial and mesenchymal pluripotential blastemic tissue (2) covered most of the stomach wall. The tissue had a thickness of  $175.9 \pm 28 \mu\text{m}$ , and was formed by a blastema rich in undifferentiated stellate cells grouped in several irregularly distributed layers.

#### Gestation days 30-32 (2-5 cm C-R)

The stomach was still a single cavity, but now

**Fig. 1.** Micrograph of the undifferentiated stomach at 26 days of gestation (HE, x 150) (1 = Epithelium; 2 = Pluripotential blastemic tissue).

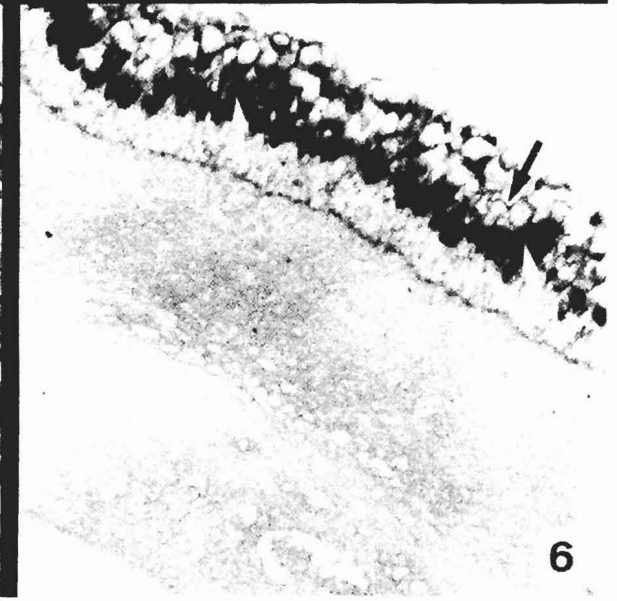
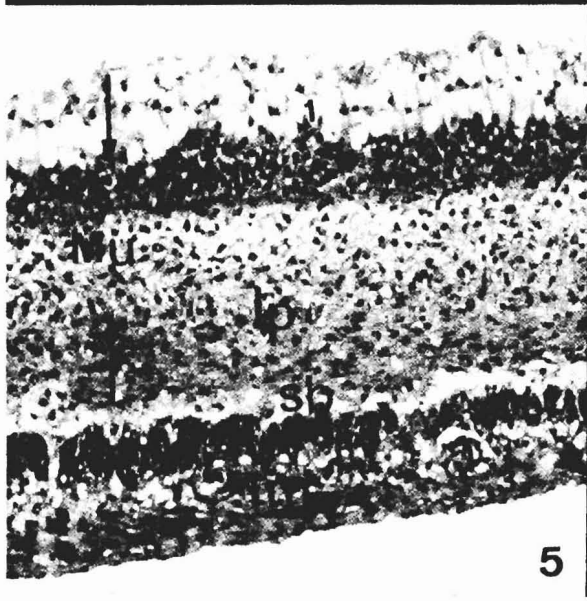
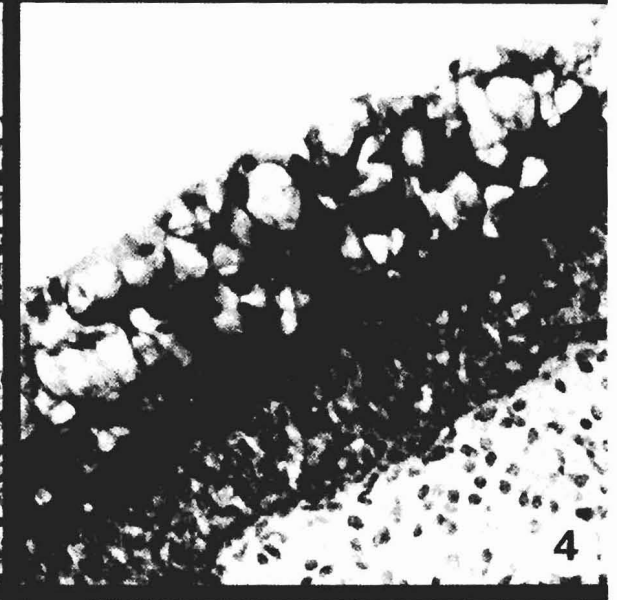
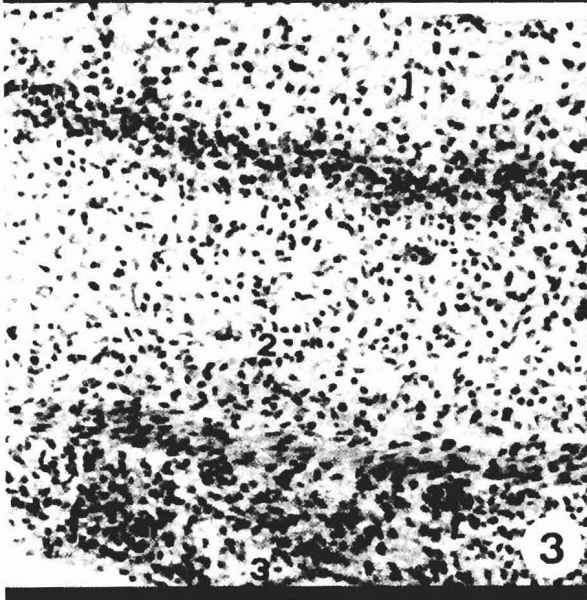
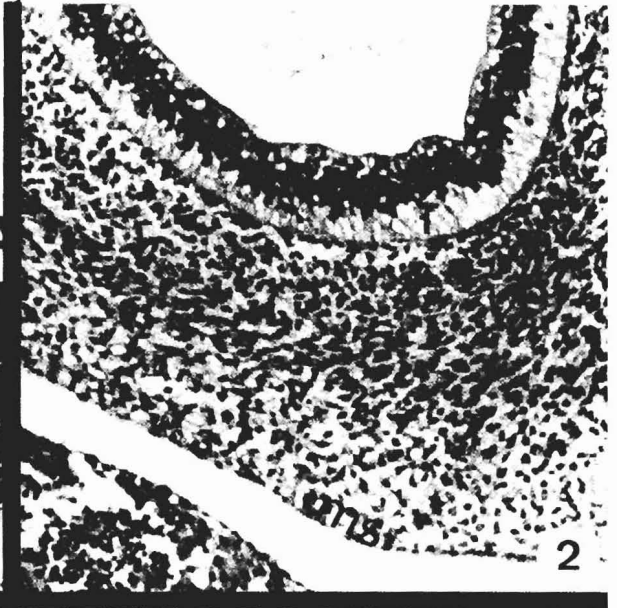
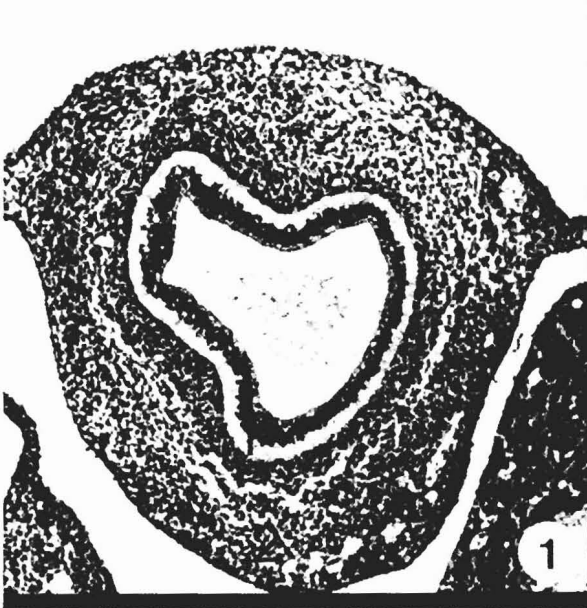**Fig. 2.** Stomach wall at 30 days of gestation (HE, x 250). (1 = Epithelium; 2 = Pluripotential blastemic tissue; 3 = Serosa; ms = mesothelium).

**Fig. 3.** Reticular wall at 33 days gestation (HE, x 250). (1 = Epithelium; 2 = Pluripotential blastemic tissue; 3 = Serosa; ms = mesothelium).

**Fig. 4.** Neutral mucopolysaccharides in epithelial cell cytoplasm at 46 days (PAS, x 350)

**Fig. 5.** Reticular wall at 53 days, showing four clearly-defined layers (HE, x 250). (1 = Epithelium; Mu = Mucosa; Lp = Lamina propria; Sb = Submucosa; Tm = Tunica muscularis).

**Fig. 6.** Reticular wall at 57 days, showing alternation of PAS-positivity (white arrow) and PAS-negativity (black arrow) in epithelium (PAS-AB, x 150)



*Development of sheep reticulum*

showed signs of the internal dilation corresponding to the different compartments. The wall was composed of three layers (Fig. 2).

The first layer (1) was internal stratified epithelium ( $62.1 \pm 8.1 \mu\text{m}$ ), formed by two bands, a larger basal band (light and anuclear) and a smaller apical band (dark and rich in nuclei). The next layer (2) was middle pluripotential blastemic tissue ( $190.3 \pm 33.5 \mu\text{m}$ ). A cluster of longitudinally-oriented fusiform cells was detected in the middle zone; this would later form the tunica muscularis.

The final layer (3), was the external serosa, formed by a single layer of flat cells (ms) (mesothelium), and subserosa composed of mesenchymatous tissue rich in cells.

Gestation days 33-38 (2.6-3.6 cm C-R)

Histodifferentiation of the reticulum took place at 33 days (Fig. 3). The wall was composed of three layers: epithelium (1), pluripotential blastemic tissue (2) and serosa (3).

The stratified epithelium (1) ( $74.9 \pm 8 \mu\text{m}$ ), consisted of two distinct zones, a basal dark-staining zone containing 4-5 layers of germinative cells with a large centrally-located nucleus, and an apical zone containing globular cells with lightly-stained cytoplasm. No positive reaction was recorded for nitrogenated polysaccharides.

Pluripotential blastemic tissue (2) ( $146.2 \pm 10.1 \mu\text{m}$ ) was formed by mesenchymatous cells and a large amount of ground substance and separated from the epithelium by a basement membrane. Within this tissue, a thin tunica muscularis (Tm) could be distinguished; this was formed by two myoblast layers oriented in circles and longitudinally.

Serosa (3) ( $66.4 \pm 4.4 \mu\text{m}$ ) was formed by a connective subserosa with an external mesothelial lining.

Gestation days 39-52 (4 to 8 cm C-R)

At 46 days, neutral mucopolysaccharides were visible in epithelial cell cytoplasm, mainly in the middle third of the epithelial layer (Fig. 4).

A large number of capillaries evident in the pluripotential blastemic tissue were interpreted as signs

of an imminent differentiation of the lamina propria and the submucosa.

Gestation days 53-79 (8.5 - 19 cm C-R)

At 53 days (Fig. 5), the wall consisted of four distinct layers: the mucosa (Mu) (formed by the epithelium (1) and the lamina propria (Lp)); the submucosa (Sb): tunica muscularis (Tm); and the serosa (3).

Two distinct zones were detected in the epithelium: a thin, darkly-stained basal layer (stratum germinativum); and a broad, lightly-stained superficial zone. Neutral mucopolysaccharides were scattered throughout the epithelium (Fig. 6). The lamina propria was formed by connective material rich in cells and fibres.

The submucosa (Sb) was highly cellular. The tunica muscularis (Tm) ( $15.9 \pm 1.2 \mu\text{m}$ ) was clearly divided into an inner circular bundle and outer longitudinally-oriented bundle. These were separated by a thin layer of pluripotential mesenchymatous tissue which contained numerous capillaries and nerve-endings.

The serosa (3) ( $52.8 \pm 2.3 \mu\text{m}$ ) was composed of a loose subserosa lined by a flat epithelium.

The first morphological differentiation of future reticular cellulae (Rc) was recorded at 64 days (Fig. 7) as simple evaginations of the epithelial stratum germinativum forming the primitive or primary reticular ribs. At 69 days the reticular cellulae ribs took the form of more prominent evaginations of the basement layer oriented towards the lightly-stained zone of the epithelium. The growth of reticular ribs involved the lamina propria without affecting the submucosa.

Gestation days 81-112 (20-31 cm C-R)

The epithelium (1) (Fig. 9;  $9667 \pm 27.9 \mu\text{m}$ ) consisted of the following layers: stratum germinativum (Sg) (formed by a single layer of cells with lightly-stained cytoplasm); stratum granulosum (Sgr) (formed by polyhedral vesicular cells); stratum lucidum/spinosum (S1-s) (poorly-defined, with large cells); stratum lucidum/spinosum (S1-s) (poorly defined, with large cells); and stratum corneum (Sc) (elongated anuclear cells arranged parallel to the surface). A slight PAS-positive reaction was detected (Fig. 10).

The lamina propria (Lp) (Fig. 9) consisted mainly of

Fig. 7. Reticular wall at 64 days showing primary reticular ribs (Cr) (HE, x 150)

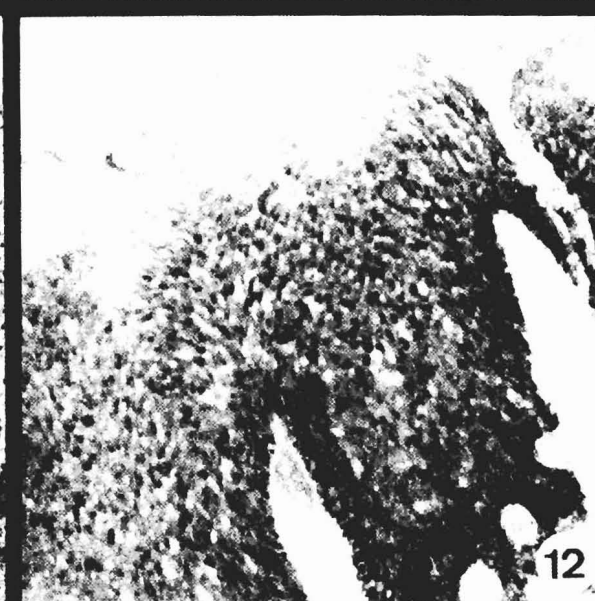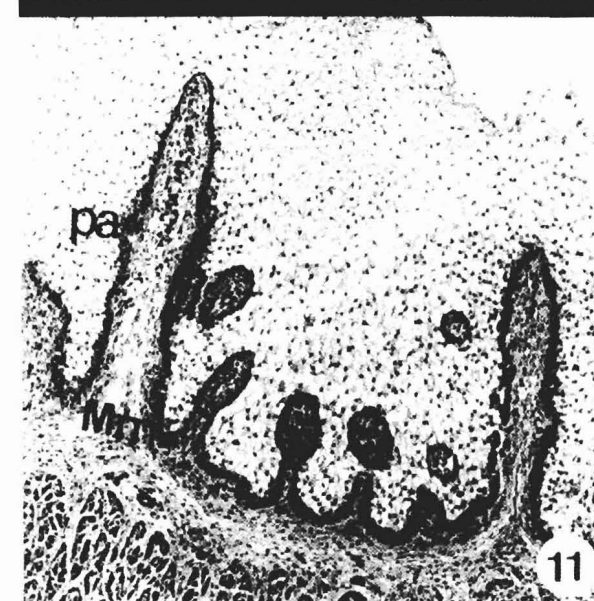
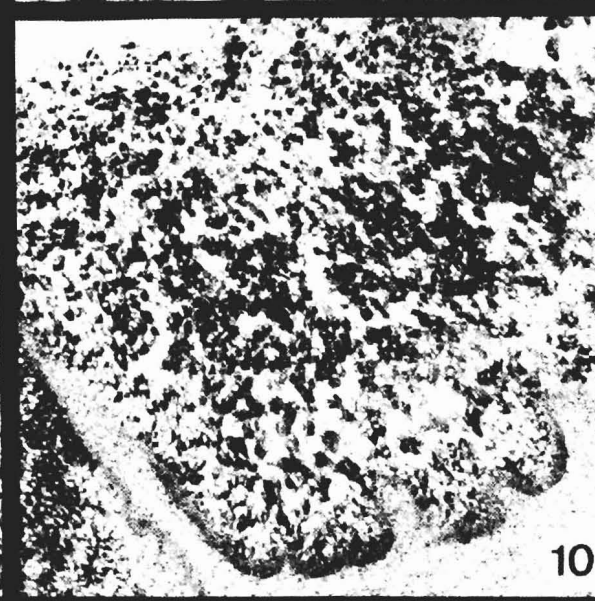
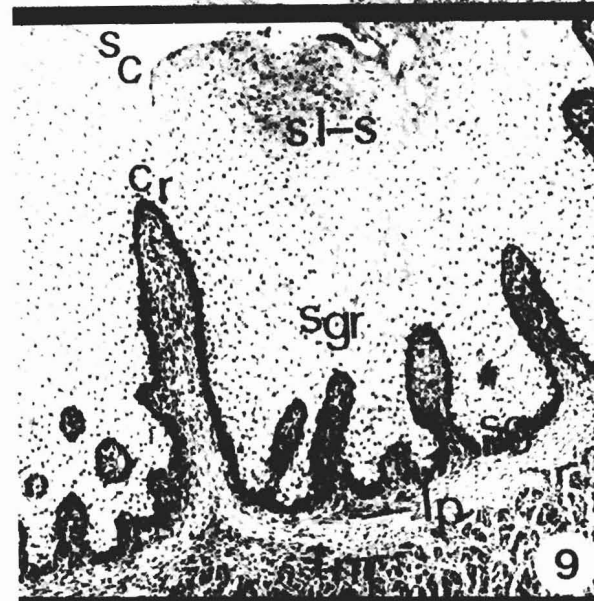
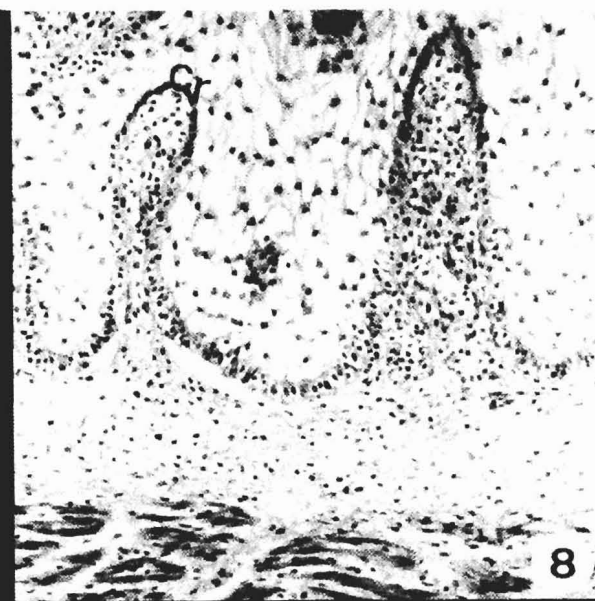
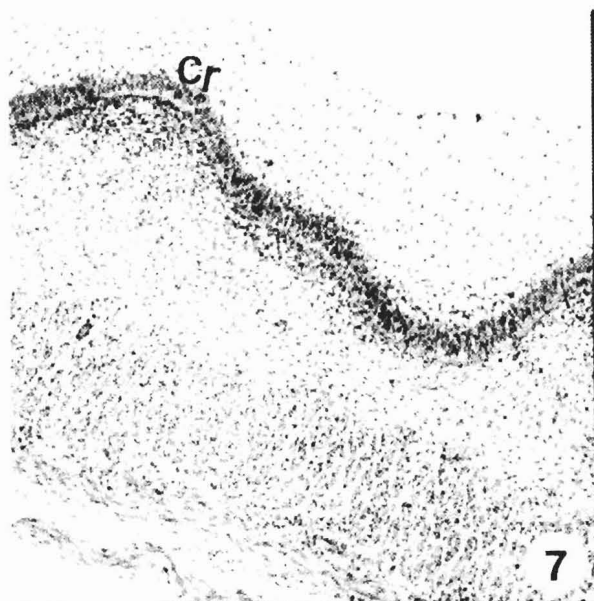
Fig. 8. Primary reticular ribs at 67 days, containing lamina propria (MT, x 350)

Fig. 9. Reticular wall at 86 days. Corial papillae visible in primary reticular ribs. Appearance of secondary ribs (MT, x 150). (Sc = Stratum corneum; S1-s = Stratum lucidum-spinosum; Sgr = Stratum granulosum; Cr = Primary reticular ribs; Lp = Lamina propria; Tm = Tunica muscularis).

Fig. 10. Ovine reticulum at 93 days. Uniform epithelial PAS positive reaction (PAS, x 350)

Fig. 11. Reticular wall at 115 days. Muscularis mucosae condensed within primary reticular ribs (VG, x 150). (pa = Corial papillae; Mm = Muscularis mucosae).

Fig. 12. Epithelium at 113 days. No neutral mucopolysaccharides in stratum corneum (PAS, x 250)



highly cellular, fibrous mesenchymatous tissue with a clear fibre arrangement. Involvement of the lamina propria in the development of primary reticular ribs (cr) led to its visible separation from the submucosa, which was rich in stellate cells.

The tunica muscularis (Tm) (Fig. 9) showed a considerable increase in thickness ( $218 \pm 38 \mu\text{m}$ ), the increase being most marked in the inner bundle. Blood vessels and bands of nerves were visible within inter- and peri-muscular connective tissue.

Primary reticular ribs (cr) continued to grow from the basement membrane towards the epithelial surface. Corial papillae were now visible as lateral projections of connective tissue from the primary ribs into the epithelium. Secondary reticular ribs were also developing from the basement membrane. These were growing in the direction of the epithelial surface, but never attained the same length as primary ribs.

#### Gestation days 113-118 (32-36 cm C-R)

The histogenic structure of the reticular wall showed few major changes with respect to the previous stage (Fig. 11), except for a discontinuity of the epithelial surface between primary reticular ribs. Lateral corial papillae (pa) were more pronounced, and the lamina propria had condensed within the primary and secondary reticular ribs and corial papillae. The muscularis mucosae (Mm) from the inner bundle of the tunica muscularis had penetrated the primary reticular ribs to form the rib musculature. Secondary ribs contained only lamina propria.

At 113 days of gestation, the PAS positive reaction was uniformly intense in the basal and middle thirds of the epithelium. Neutral mucopolysaccharides were not detected in the stratum corneum (Fig. 12), but by 117 days they were seen to be arranged in the basal zones of the epithelium in such a way that the reticular cell had a PAS positive border (Fig. 13).

#### Gestation days 120-150, foetuses at term (37-40 cm C-R)

The epithelium (1) was squamous, stratified, flat and non-keratinized. The decrease in neutral mucopolysaccharides, already observed in the previous stage, reached its maximum at birth. PAS-negative clearly outnumbered PAS-positive cells (Fig. 14). No evidence

was recorded of acid mucopolysaccharides, mucins or mucoid compounds.

The lamina propria (Lp) (Fig. 15), rich in elastic and collagen fibres, was highly vascularized, especially in the reticular ribs.

The muscularis mucosae (Mm) was particularly evident in primary ribs. Muscle bundles projected from one rib to the next, thus forming a continuous network of muscle tissue throughout the reticular mucosa (Fig. 16).

The submucosa (Sb) (Fig. 15), consisting of a loose arrangement of elastic and collagen fibres, was not clearly separated from the lamina propria.

The tunica muscularis (Tm) consisted of two layers of smooth muscle tissue oriented in inner circular and outer longitudinal directions. The serosa (3) was formed by loose mesenchymatous connective tissue with a thin mesothelial lining (Fig. 15).

Scanning electron microscopy (Fig. 17) showed the reticular surface to consist of small reticular cells with fairly low ribs. The cell area bounded by the ribs contained rudimentary reticular papillae. Poorly-developed papillae were found to alternate with extremely long papillae; these were rounded and conical in shape, and revealed no evidence of desquamation or keratinization.

#### Postnatal development (2days-2years)

The histological characteristics of tissue strata had reached their definitive form in the previous phase. SEM analysis of the reticular mucosa (Fig. 18) showed an increased in size of the reticular cells; ribs were papillae. There was some keratinization of the papillar surface.

#### Histochemical behaviour of the epithelium

Neutral mucopolysaccharides appeared from day 46 of foetal development. A positive reaction was noted over  $62.7 \pm 6\%$  of a reference surface area of  $100 \mu\text{m}^2$ . The percentage of PAS-positive reactions increased by day 79 ( $76.2 \pm 7\%$ ) to reach maximum values at 88 days ( $93.3 \pm 4\%$ ). Thereafter, values started to decrease ( $82.5 \pm 5\%$  at 117 days and  $18.6 \pm 9\%$  at birth), stabilising during postnatal development at  $13.2 \pm 6\%$ . Acid mucopolysaccharides, mucins and mucoid compounds were not found during development.

Fig. 13. Reticular cell (c) at 117 days. Neutral mucopolysaccharides uniformly distributed throughout basal zones of epithelium (PAS x 250)


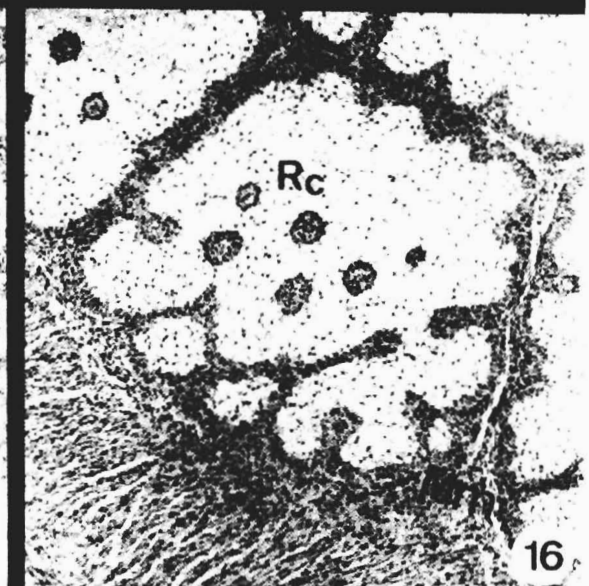
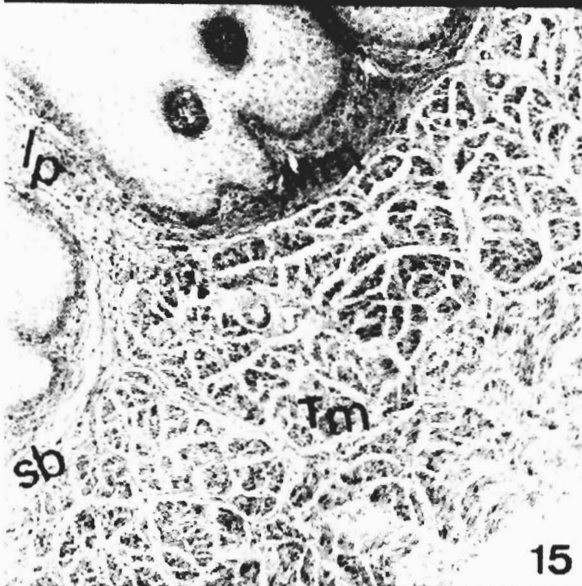
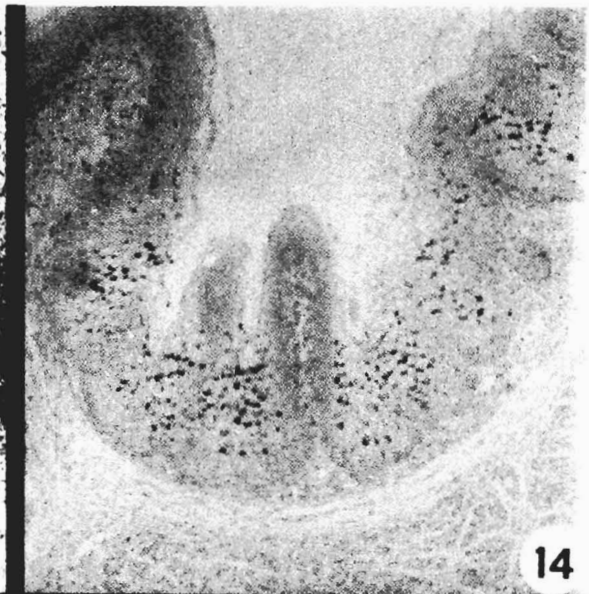
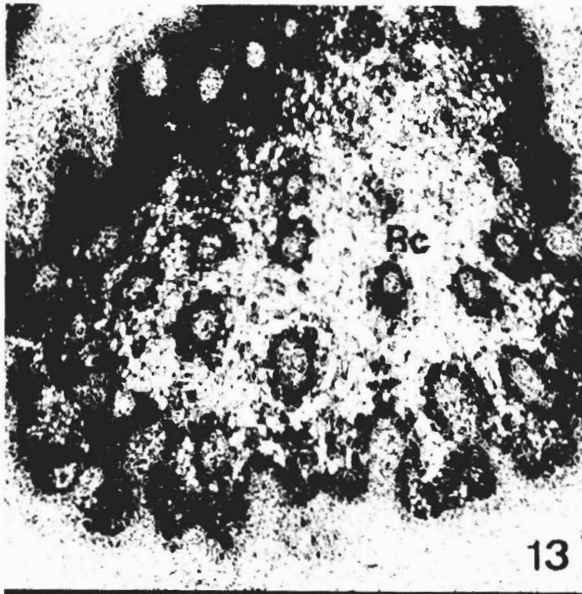
Fig. 14. Negligible amount of neutral mucopolysaccharides in sheep epithelium at birth (PAS-AB, x 250)

Fig. 15. Reticular wall at birth (VG x 250). (Lp = Lamina propria; Mm = Muscularis mucosae; Sb = submucosa; Tm = Tunica muscularis).

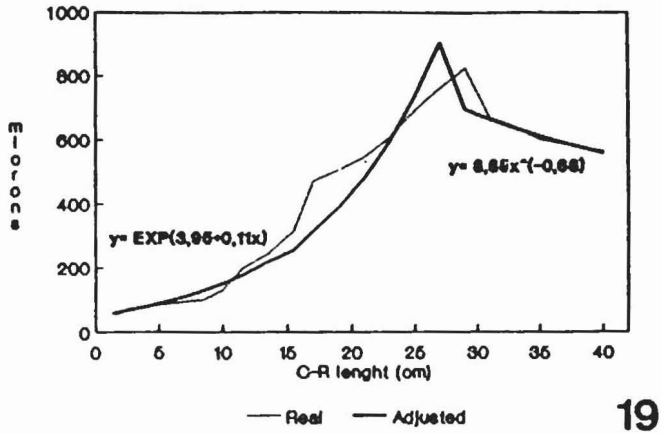
Fig. 16. Reticular wall at birth. Muscularis mucosae visible within primary ribs (HE, x 250). (RC = Reticular cellulae; Mm = Muscularis mucosae).

Fig. 17. Micrograph of reticular surface at birth (SEM, x 200)

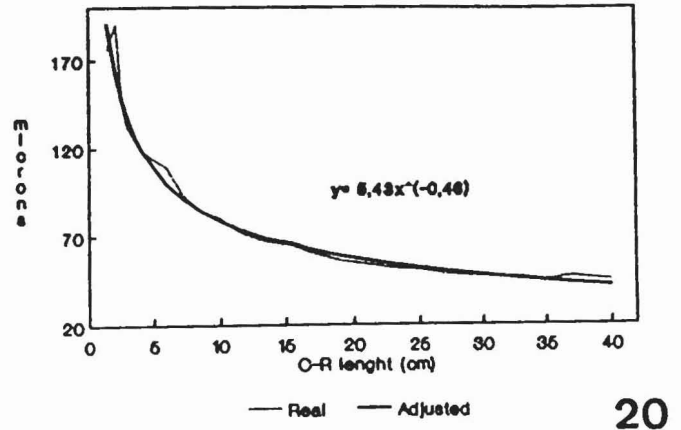
Fig. 18. Reticular ribs and papillae in adult sheep (SEM, x 50)



Development of sheep reticulum



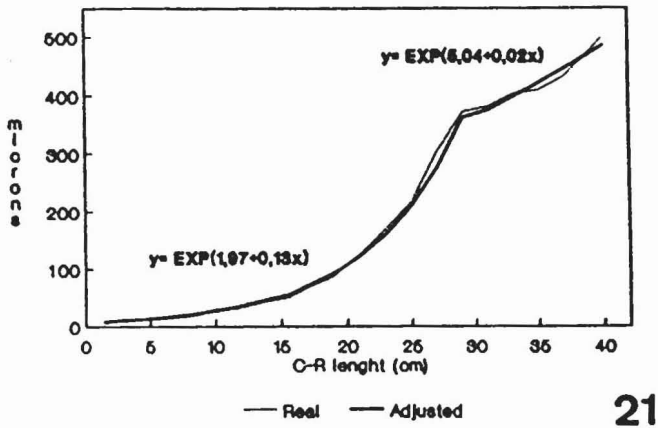
19



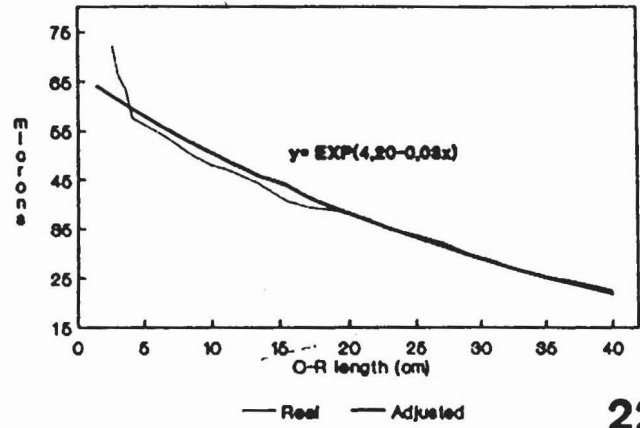
20

Fig. 19. Model of reticulum growth (epithelium).

Fig. 20. Model of reticulum growth (lamina propria + submucosa)



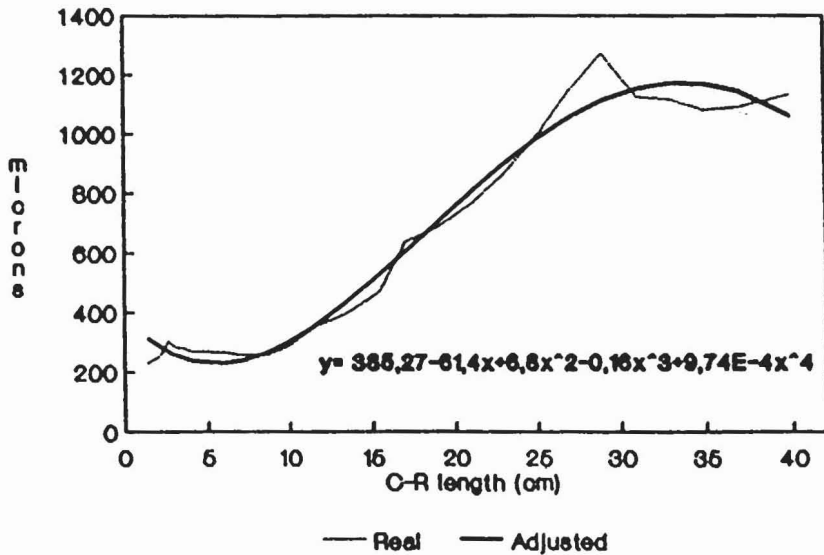
21



22

Fig. 21. Model of reticulum growth (tunica muscularis).

Fig. 22. Model of reticulum growth (serosa).



23

Fig. 23. Model of reticulum growth (wall).



## Development of sheep reticulum

### Histomorphometric analysis

Fit of each tissue stratum to mathematical growth models is shown in Figs. 19-22, together with its corresponding growth equation.

### Discussion

At 23 days of foetal life (0.4 cm C-R), the stomach wall was already structured in two layers: the epithelium and the pluripotential blastemic tissue (Vivo et al., 1990). These were primitive indistinct structures, with high blastic capacity (Warner, 1958).

The reticulum was first observed in certain samples at 33 days (2.6 cm C-R). The pseudostratified epithelium (Warner, 1958) lacked secretory capacity. Evidence of stratification was not detected until 53 days (8.5 cm C-R). By 83 days, stratum corneum and stratum lucidum/spinosum had been added to the two initial layers (stratum germinativum and stratum granulosum). Few authors actually define these strata; indeed, some make no reference to stratum lucidum and stratum spinosum at all (Tiwari and Jamdar, 1970; Osman and Berg, 1981). The definitive structuring of the epithelium is reflected histomorphometrically in increased thickness and the formation of primitive reticular cells at 69 days of prenatal development (13.5 cm C-R). The first appearance of reticular cells is reported in sheep at 16.5 cm (Del Rio Ortega, 1973) and 24 cm (Fath El-Bab et al., 1983). Molinari and Jorquera (1988) detected cells in goats between 14.9 cm and 28.3 cm, while they are first detected in buffalo at 14.5 cm (Panchamukhi and Srivastava, 1979) and in cattle at 50 cm C-R (Osman and Berg, 1981). In this study, corial papillae were first detected in primary reticular ribs at 83 days (21 cm C-R). Although Fath El-Bab et al. (1985) report papillae at 24.5 cm in sheep and Panchamukhi and Srivastava (1979) at 74 cm in buffalo, papillae were not detected until birth by Del Rio Ortega (1973) and Molinari and Jorquera (1988) in sheep and goats, respectively. Secondary reticular ribs, always smaller than primary ribs, were also found here at 83 days. Fath El-Bab et al. (1985) report secondary ribs at 30 cm, Del Rio Ortega (1973) at 26 cm, Molinari and Jorquera (1988) at 28.3 cm and Panchamukhi and Srivastava (1979) at 25.5 cm C-R.

The formation of reticular cells requires growth of ribs in two directions; longitudinally towards the epithelial surface and laterally to connect with adjacent ribs. The difference in size of reticulum cells may be due to variations in the height of primary and secondary reticular ribs.

At 33 days of gestation (2.3 cm), a thin tunica muscularis becomes distinct from the pluripotential blastemic tissue; the tunica is formed by two layers of myoblasts of circular and longitudinal orientation. First evidence of the tunica muscularis is reported at 52 days by Fath El-Bab et al. (1985), at 34 days by Duncan and Phillison (1955) and at 50 days by Del Rio Ortega

(1973). At 113 days (33 cm), the muscularis mucosae arising from the inner bundle penetrates and condenses within reticular ribs, thus participating in their formation. This coincides with increased thickness of the tunica muscularis and development of reticular cells. Of the few references made to the muscularis mucosae in the literature available, Panchamukhi and Srivastava (1979), in studies of the buffalo forestomach, and Wardrop (1961), in studies of sheep, report a band of smooth muscle growing towards the core of the primary fold. This takes place during the perinatal period in buffalo and the postnatal period in sheep.

The first appearance of the lamina propria and the submucosa, both derived from the pluripotential blastemic tissue (Wardrop, 1961), was noted at 53 days of gestation (8.5 cm C-R). A certain degree of continuity (both in growth and in differentiation) was observed in the serosa from the earliest stages of gestation onwards.

SEM analysis of the reticular mucosa suggest that age and diet are determining factors in the structural development of reticular ribs and papillae. The transition from the milk diet of the newborn lamb to food with a medium-to-high fibre content requires increased competence from the reticular wall, giving rise to a two fold mechanism: 1. Strengthening of the mucosa, morphologically evident in epithelial expansion (growth recorded morphometrically); and 2. Muscle contraction, as a direct result of contraction of the inner bundle (Scott and Gardner, 1973; McGavin and Morril, 1976).

We believe that the mechanical protection of the reticular mucosa against damage which may give rise to the first products of embryonic metabolism is a function located in the stratum corneum, where no neutral polysaccharides were detected. Neutral polysaccharides present in deeper epithelial layers from 46 days of gestation until birth, as well as participating directly in the epithelial maturing process, may also serve as a defensive barrier against acid substances found in amniotic fluid, which is routinely swallowed during gestation (Dellman and Brown, 1981; Moore, 1985).

### References

- Amasaki H. and Daigo M. (1987). Prenatal development of subepithelial vasculature related to appearance of ruminal papillae in the bovine omasum. *Anat. Anz.* 164, 139-147.
- Del Rio Ortega S. (1973). Desarrollo prenatal del estómago de la oveja-*ovis aries*- MS Thesis. University of Zaragoza.
- Dellman H. and Brown E. (1981). Textbook of veterinary histology. Lea and Febiger (eds). Philadelphia.
- Duncan D.L. and Phillison A.T. (1955). The development of motor responses in the stomach of the foetal sheep. *J. Exp. Biol.* 28, 32-40.
- Fath-El Bab M.R., Schwart R. and Ali A.M.A. (1983). Micromorphological studies on the stomach of sheep during prenatal life. *Anat. Histol. Embryol.* 12, 139-153.
- Franco A., Regodón S., Robina A. and Redondo E. (1992). Histomorphometric analysis of the rumen of sheep during development. *Am. J. Vet. Res.* 53, 1209-1217.

*Development of sheep reticulum*

- Mc Gavin M.D. and Morrill J.L. (1976). Scanning electron microscopy of ruminal papillae in calves feed various amounts and forms of roughage. *Am. J. Vet. Res.* 37, 497-507.
- Molinari E. and Jorquera B. (1988). Intrauterine development stages of the gastric compartments of the caprine *Capra hircus*. *Anat. Histol. Embryol.* 17, 121-137.
- Moore K.L. (1985). *Embriologia clinica*. Interamericana. Mexico. pp 262-273.
- Osman A.H.R. and Berg R. (1981). Studies on the histogenesis of the tunica mucosa of the stomach of the egyptian water buffalo (*Bos bubbalis*). 1. Histogenesis of the ruminal mucosa. *Anat. Anz.* 149, 232-240.
- Panchamukhi B.G. and Srivastava H.C. (1979). Histogenesis of the omasum of the buffalo (*Bubalus bubalis*) stomach. *Anat. Histol. Embryol.* 8, 97-105.
- Schwartz V. (1977). *Embriologia animal comparada*. Omega (ed). Barcelona.
- Scott A. and Gardner J.C. (1973). Papillar form in the forestomach of the sheep. *J. Anat.* 116, 255-267.
- Tiwari J.P. and Jamdar M.N. (1970). Studies on gross and histological of development of the forestomachs of indian water buffalo calf in early postnatal life with reference to normal feeding. 1 Rumen. *Ind. J. Anim. Sci.* 57, 335-340.
- Trautman A. and Fiebiger J. (1957). *Fundamentals of the histology of domestic animals*. Comstoks (ed). New York.
- Vivo J.M., Robina A., Regodón S., Guillén M.T., Franco A. and Mayoral A.I. (1990). Histogenetic evolution of bovine gastric compartments during the prenatal period. *Histol. Histopath.* 5, 461-476.
- Wardrop J.D. (1961). Some preliminary observations on the histological development of the forestomach of the lamb. I. Histological changes due to age in the period from 46 days of foetal life to 77 days of postnatal life. *J. Agric. Sci.* 57, 335-341.
- Warner E.D. (1958). The organogenesis and early histogenesis of the bovine stomach. *Am. J. Anat.* 102, 33-63.

Accepted April 5, 1993