

Histogenetic evolution of bovine gastric compartments during the prenatal period

J.M. Vivo, A. Robina, S. Regodón, M.T. Guillén, A. Franco and A.I. Mayoral

Department of Anatomy and Embryology, Faculty of Veterinary, University of Extremadura, Cáceres, Spain

Summary. In order to carry out this study, 62 embryos and fetuses of Friesian cows were used, and every stomach was dissected and subjected to the usual laboratory procedures. After obtaining each preparation all the histological and metrical changes that took place in the wall of the viscus during its development are described.

The compartments are histologically differentiated into three stages: in the first one there is no compartment differentiation: in the second one, the rumino-reticulum, omasum and abomasum have differentiated; and in the third one every compartment is differentiated. In group 16, (78 days of gestation), a decrease in thickness of the muscular layer of all compartments, parallel to the histological differentiation has been observed.

Key words: Histogenetic, Gastric compartments, Bovine, Prenatal

Introduction

The development of the compound stomach in ruminants has attracted attention with regard to morphogenetic and histogenetic aspects in the past. Our present aim is to profoundly and exclusively look at the histogenetic side, and those morphometric connotations that can be drawn from the study of the gastric viscus of bovine embryos and fetuses.

Lambert (1948) considers the gastric epithelial coating to be a distinguishing characteristic of the CR-30 cm embryo. Some years later, Warner (1958) makes a more profound study of its histogenesis, pointing out some of the cyto-histological modifications that take place in the wall of the stomach-to-be.

Birgele (1969) refers to the histogenesis of the mucoid

cells in the fundic mucosa of the abomasum, as well as to the delimitation of accessory cells in the mucosa of this bovine gastric compartment. Arias et al. (1978) deal with the histological development of the ruminal papillae in cows and affirm that their formation begins when the fetus is 5 months old.

Sengar and Singh (1969), together with Pancharukhi et al. (1977 to 1982), are the researchers who study the histogenesis of the stomach in greatest depth, describing this process within the four compartments, and using embryos and fetuses of buffalo (*Bos bubalis*) as experimental material. Kano (1981) does so in the same way in Holstein-Friesian bovines. More recently Molinari and Jorquera (1988) describe caprine fetuses of over 70 days of age from a histological point of view.

We have not found any references to morphometric aspects applied to the different structural layers of the bovine stomach during our bibliographic review. Despite this fact, we are convinced that these aspects are of interest, and we therefore take them into account in our study.

Materials and methods

62 Frisian cow embryos and fetuses were used, 42 of them coming directly from the slaughterhouse, the specimens being extracted at the very moment of opening the genital apparatus. The helpful contribution of official vets in the province of Cáceres provided us with the remaining 20 obtained during their daily clinical work.

Each specimen was injected with 10% formol via the umbilicus, the quantity varying depending on the size of the embryo or fetus. Immediately afterwards, they were immersed in containers full of the same fixative.

Size and age verifications of the material were always made at the very moment of collection. As for the method, the one used by Evans and Sack (1973) was chosen from among those by the different authors reviewed (Nichols, 1944; Postma, 1947; Kurnosov, 1960;

Evolution of bovine gastric compartments

Thomsen, 1975), because we believe that they have managed to put together and clarify what had previously been done, simplyfying and setting it out in a highly precise and sensible way. Although, obviously, their growth curves and tables showing outer morphological characteristics are not exact, they are precise enough to be regarded as a standard to follow.

The material used in the experiment, collected and preserved as described above, was distributed into groups as indicated in Table 1.

Table 1.

GROUPS	C-R LENGTH cm	NUMBER OF SPECIMENS PER GROUP	AGE (Days)
1	1.30	3	23
2	1.70	3	30
3	2.20	3	36
4	2.50	3	38
5	3.00	3	40
6	3.30	3	42
7	4.20	3	44
8	4.70	3	48
9	5.50	3	52
10	6.50	3	57
11	7.00	3	60
12	7.50	3	62
13	7.80	3	64
14	9.50	3	70
15	10.50	2	73
16	11.50	2	78
17	13.00	2	85
18	15.00	2	90
19	16.50	2	95
20	24.00	2	120
21	30.00	2	135
22	62.00	2	210
23	80.00	2	240
24	95.00	2	280

The specimens were put through the usual procedure followed in optical microscopy in the histology laboratory: preparation of tissues, formation of paraffin blocks, microtome cut (from 2 to 10 micra) and staining with hematoxylin-eosin. The four compartments of each specimen were cut at the same parietal levels: cranial side in the reticulum; the largest and thickest parts

of the dorsal and ventral edges in the rumen; medial areas in the parietal side of the omasum; and the central levels of the major curvature in the abomasum. Each cut was perpendicular to the wall of its respective compartment.

The preparations were examined through the microscope and the most significant ones were photographed. We also present a macro-scheme where all the histological differences shown in this study can be observed as a whole.

The parietal layers of the four gastric compartments were measured by means of an image analyser. These measurements were put to a multiple lineal regression analysis in order to obtain their corresponding curves.

Results

1.- Histogenetic analysis

In order to obtain a better layout of this section it was considered convenient to classify the data obtained from the analysis of the specimens used in the experiment into three large groups: to do so the classification was based on the most distinctive histogenetic transformations which were perceived during the developmental stages. In the first stage, the histological constitution of the stomach when there was still no compartment division was studied; in the second stage, the structural distinction between the rumino-reticular block (as a whole), and the omasum and abomasum was apparent; lastly (third stage) the walls of the four compartments were totally defined.

Stage A.- Groups 1 to 6 (from the 23rd to 42th days of gestation).

The four gastric compartments were still not differentiated on the 23rd day of gestation (C-R 1.3 cm, Fig. 1). The stomach was spindly and the histogenetic constitution was alike in all of them. The wall was made up of an epithelial lamina (el), pluripotential blastic tissue (pbt) and a serosa (se). The epithelial lamina consisted of a stratified epithelium whose cells varied from a cubic to a prismatic shape with a nucleus facing in the direction of the basal membrane (bm). The pluripotential blastic tissue contained star-shaped cells with vesiculose nuclei and a large amount of fundamental substance. Lastly, the serosa was formed by a flat epithelium.

Starting from this essential histogenetic constitution, which is initially valid for the four compartments, we will talk about the different transformations that take place, pointing them out within the parietal substratum which is affected.

Thus, when the fetus was 30 days old (C-R 1.7 cm., Fig. 2) we notice the appearance of a cellular layer (cl) in the reticulum facing in the direction of the epithelium; situated within the pluripotential blastic tissue. This cellular layer also appeared in the omasum and abomasum with a myoblastic nature.

Table 2. Rumen

GROUPS	EPITHELIUM	PLURIPOTENTIAL BLASTIC TISSUE	LAMINA PROPRIA	SUBMUCOSA	MUSCULAR TUNIC	SEROSA
1	47.69	237.78			0	0
2	51.07	165.93			24.36	130.10
3	60.41	198.46			19.28	126.53
4	66.68	186.24			14.23	55.82
5	51.69	114.07			15.76	82.34
6	79.60	132.79			19.78	86.05
7	85.06	166.29			31.04	69.54
8	93.62	103.46			31.78	23.40
9	102.29	150.98			39.33	18.64
10	99.43	181.63			47.77	24.74
11	103.45		114.68	80.49	38.40	22.87
12	106.67		86.48	89.50	28.63	22.69
13	130.67		72.25	110.36	37.63	26.48
14	182.08		172.29	216.02	75.90	38.93
15	296.29		65.17	99.01	63.95	25.16
16	113.36		81.99	101.21	71.09	29.21
17	324.13		90.23	118.24	109.07	37.06
18	134.97		48.99	116.30	95.43	51.18
19	267.04		74.50	121.77	145.86	57.43
20	376.39		52.09	142.69	130.30	15.41
21	401.20		64.68	150.91	333.42	32.65
22	430.21		60.21	151.22	426.50	58.43
23	460.18		50.10	158.20	350.20	29.20
24	501.30		62.90	237.80	387.40	36.87

At 36-38 days (C-R 2.2 and 2.5 cm., Fig. 3) a distinctive detail should be pointed out: the appearance of the cellular (cl) layer in the rumen. At 40-42 days (C-R 3 and 3.3 cm, Fig. 4) a large layer of pluripotential blastic tissue was observed in the omasum and abomasum, with a large quantity of fundamental substance. This layer gave rise to incipient folds which affected the inner parts (epithelial lamina): primary folds (f1) in the omasum; and abomasal folds (af).

Stage B.— Groups 7 to 16 (from the 44th to 78th days of gestation).

Up to this point those groups where the different gastric compartments cannot be distinguished yet by examining the evolution of the parietal tissues have been described. From this moment the first separation took place due to a process of histodifferentiation: on the one hand, the rumino-reticular block could be

seen and on the other, the omasum; the abomasum would take an independent shape too.

In groups 7 and 8, corresponding to the period between days 44 and 48 (C-R 4.2 and 4.7 cm, Fig. 5) the cellular layer, which was now changing to a myoblastic layer with spindly cells, was starting to transform itself into the muscular tunic (mt). The secondary folds (f2) began to appear within the omasum (Fig. 6), and two fasciculi started to shape in its muscular tunic (mt): a circular and a longitudinal one. The myoblastic cells that would form the muscular layer of the mucosa (mm) later on migrated from the muscular tunic towards the folds.

By days 52 and 57 (C-R 5.5 and 6.5 cm) one could already notice that the tertiary folds (f3) were just coming into sight in the omasum (Fig. 7). The previously defined folds in the abomasum (Fig. 8) showed basic villi (vi), and it was evident that the blastic tissue was going to transform itself into the lamina propria

Evolution of bovine gastric compartments

Table 3. Reticulum

GROUPS	EPITHELIUM	PLURIPOTENTIAL BLASTIC TISSUE	LAMINA PROPRIA	SUBMUCOSA	MUSCULAR TUNIC	SEROSA
1	47.69	237.78			0	0
2	48.29	112.23			12.50	68.21
3	47.48	160.39			8.99	69.19
4	44.94	118.51			13.38	88.79
5	83.23	94.85			13.37	56.93
6	64.05	186.27			18.50	65.42
7	145.05	214.86			37.62	80.37
8	206.89	145.09			30.22	37.50
9	83.43	220.45			52.95	33.50
10	87.89	272.40			64.49	23.65
11	120.27		135.89	88.09	58.73	27.03
12	142.70		107.30	95.80	52.80	31.80
13	192.69		166.03	84.03	61.41	33.54
14	257.07		203.33	110.86	133.54	51.81
15	273.57		102.32	148.09	109.45	59.59
16	221.66		96.29	66.49	57.15	29.33
17	229.25		87.78	72.07	125.30	33.57
18	239.58		33.10	65.85	92.95	38.09
19	291.07		19.88	19.88	61.64	60.53
20	975.60		48.54	33.69	248.43	48.79
21	120.01		49.81	41.35	318.23	23.91
22	398.15		54.15	63.12	422.47	25.26
23	184.90		39.30	72.40	520.69	27.18
24	205.50		29.20	151.10	567.01	40.60

and submucosa because of the appearance of vascular nets and fibroblastic cells.

In groups 11, 12 and 13, corresponding to 60, 62 and 64 days (C-R 7,7.5 and 7.8 cm) it was noticed that the germinal zone (gz) of the rumino-reticular block (Fig. 9) was actively proliferating, and its blastic tissue shows the lamina propria (lp) and submucosa (sm). The primary (f1), secondary (f2) and tertiary folds (f3) stood out in the omasum (Fig. 10); the mucosa showed the lamina propria (lp) coming from the muscular layer and a layer of myoblasts. This layer of myoblasts already acted as the muscular layer of the mucosa (mm) and the submucosa (sm) also appeared now. The folds in the abomasum (Fig. 11) revealed expanding villi (vi). The narrow lamina propria (lp) and submucosa (sm) occupied a larger space.

From days 70 to 78 (C-R 9.5 to 11.5 cm) the quaternary folds (f4, Fig. 12) seemed to be formed in the omasum,

and the muscular layer of the mucosa (mm) was more developed. There was a noticeable modification in the epithelial layer of the abomasum (Fig. 13): it changed from a stratified structure to a cylindrical one, and presented villi (vi) of irregular morphology, although they were well-formed in the abomasal folds.

Stage C.- Groups 17 to 24 (from the 85th day to birth)

In the third and final group histoparietal differences could already be distinguished between the four gastric compartments.

At 85 days (C-R 13 cm) a remarkable fact in the muscular tunic of the rumen could be observed (mt, Fig. 14): its division into two fasciculi. An inner one, which was circular and oblique, and an outer one, which was longitudinal. On the other hand, some primitive crests were becoming apparent in the reticulum (rcr,

Table 4. Omasum

GROUPS	EPITHELIUM	PLURIPOTENTIAL BLASTIC TISSUE	LAMINA PROPRIA	SUBMUCOSA	MUSCULAR TUNIC	SEROSA
1	47.69	237.78			0	0
2	50.57	87.18			21.98	153.89
3	54.04	75.24			13.29	134.52
4	59.84	95.86			19.26	89.63
5	44.89	56.43			18.06	68.94
6	57.58	70.49			31.94	44.85
7	51.03	77.76			47.17	40.68
8	47.25	55.26			87.02	43.14
9	42.90	60.33			62.41	31.16
10	38.28	52.99			77.50	32.79
11	36.56		50.98	45.65	77.41	33.89
12	35.10		50.43	47.47	77.26	36.55
13	37.64		48.60	61.87	88.11	37.36
14	43.22		62.52	64.06	109.21	37.88
15	68.11		79.88	72.19	66.22	34.61
16	51.47		49.40	48.17	67.61	24.08
17	70.76		59.34	50.75	108.91	63.41
18	71.03		74.50	35.77	11.10	33.34
19	73.77		61.81	32.46	164.18	59.44
20	86.68		37.66	4.10	196.21	42.65
21	91.19		39.18	51.80	234.47	33.02
22	198.43		41.79	63.36	284.12	27.22
23	109.50		50.20	78.50	338.20	26.19
24	75.70		33.70	80.18	370.10	24.12

Fig. 15) facing in the direction of its epithelium. The muscular tunic (mt) of the reticulum was made up of two fasciculi: the inner one was circular and oblique, and the outer one, longitudinal. No differences, either in the omasum, or in the abomasum, were detected between this group and the previous ones at this age.

Between days 90 and 95 (C-R 15 and 16.5 cm) some specific details were observed: many crests in the reticulum penetrated into the epithelium (rcr, Fig. 16); the omasum showed thinner and sharper folds (Fig. 17); there were marked villi in the abomasum; and the muscular tunic, the only structure which was still undefined, was preparing to do so.

At 4 and 4.5 months (C-R 24 and 30 cm) small papillae were perceived in the rumen (rup, Fig. 18), coming out from the underlying tissue towards the epithelium. As for the reticulum (Fig. 19), its crests (rcr) continued to penetrate into the epithelium, in which

the typical reticular cells were already forming (rc). The muscular layer of the mucosa (mm) in the omasum (Fig. 20) was evident at this stage, and, with regard to the abomasum (Fig. 21), two things should be emphasized; the division of the muscular tunic (mt) into an inner (circular) and an outer (longitudinal), and very well-marked villi (vi).

From 7 months to birth (C-R 62 to 95 cm) only complementary histogenetic processes took place (morphology and portions of folds, maturing of the layers already formed, etc.): the papillae of the rumen (rup, Fig. 22) began to rise towards the epithelium of the mucosa; the crests in the reticulum (rcr, Fig. 23) clearly reached the surface of the epithelium. This is why the reticular cells were now completely differentiated. In this sense, the presence of sharp corneous papillae (rp) at the bottom of these cells should be pointed out. The folds (or laminae) of the omasum were covered with a great

Table 5. Abomasum

GROUPS	EPITHELIUM	PLURIPOTENTIAL BLASTIC TISSUE	LAMINA PROPRIA	SUBMUCOSA	MUSCULAR TUNIC	SEROSA
1	47.69	237.78			0	0
2	55.26	99.95			17.46	56.10
3	48.69	145.57			10.58	55.25
4	49.58	155.27			15.61	55.48
5	49.60	187.53			20.35	46.72
6	61.19	223.22			13.16	43.67
7	47.66	135.95			30.59	29.68
8	35.52	65.61			28.91	28.20
9	42.43	87.19			37.04	28.94
10	51.22	77.60			44.53	29.24
11	43.38		60.33	33.25	56.80	27.88
12	36.59		43.47	34.09	69.87	26.37
13	43.65		45.30	66.35	87.45	33.38
14	43.86		90.84	74.58	86.20	45.76
15	24.43		75.17	92.12	85.32	21.14
16	21.10		54.90	66.12	61.46	29.77
17	22.63		63.62	72.94	98.09	35.76
18	14.53		72.28	83.84	106.53	37.06
19	22.07		77.74	81.49	112.56	49.78
20	14.81		70.02	82.30	204.90	16.40
21	16.75		59.50	90.24	274.22	15.34
22	16.84		56.47	91.01	450.68	21.61
23	13.80		43.20	91.80	633.01	20.70
24	11.27		38.24	93.20	785.70	21.43

deal of papillae (op, Fig. 24). As for the abomasum (Fig. 25), the most remarkable aspects were the simple cylindrical epithelium and the large number of villi which extended over the surface of the mucosa so that the latter could carry out its characteristic glandular function.

2.- Morphometric analysis

In Tables 2, 3, 4 and 5 growth values corresponding to the different organic parietal strata are quantitatively shown. The analysis of these values drew attention to the following points:

- The serosa and subserosa revealed a steady development in the four gastric compartments: initially they were large layers in predifferentiation stages, which gradually diminished until finally these strata (already defined) were found with mean values within a narrow rate of oscillation in the different compartments.

- The muscular tunic, considered as a whole, without taking into account quantitatively its consistent fasciculi, was getting thicker and thicker as the fasciculi were differentiating; it reached the highest values in the abomasum, followed by the reticulum, and finally the rumen and omasum, both with a similar height.

Something remarkable related to this layer was detected: a relevant decrease in this tunic in all the compartments up to group 16, although it returned to its steady growth later on.

This decrease took place approximately on day 78, precisely when the four compartments could be histogenetically distinguished.

- The pluripotential blastic tissue appeared as a large layer, which diminished as it progressively transformed itself into the lamina propria and submucosa. As for these, they revealed homogeneous values that had a different meaning with regards to the rumen and

Chart 1. Model of rumen growth

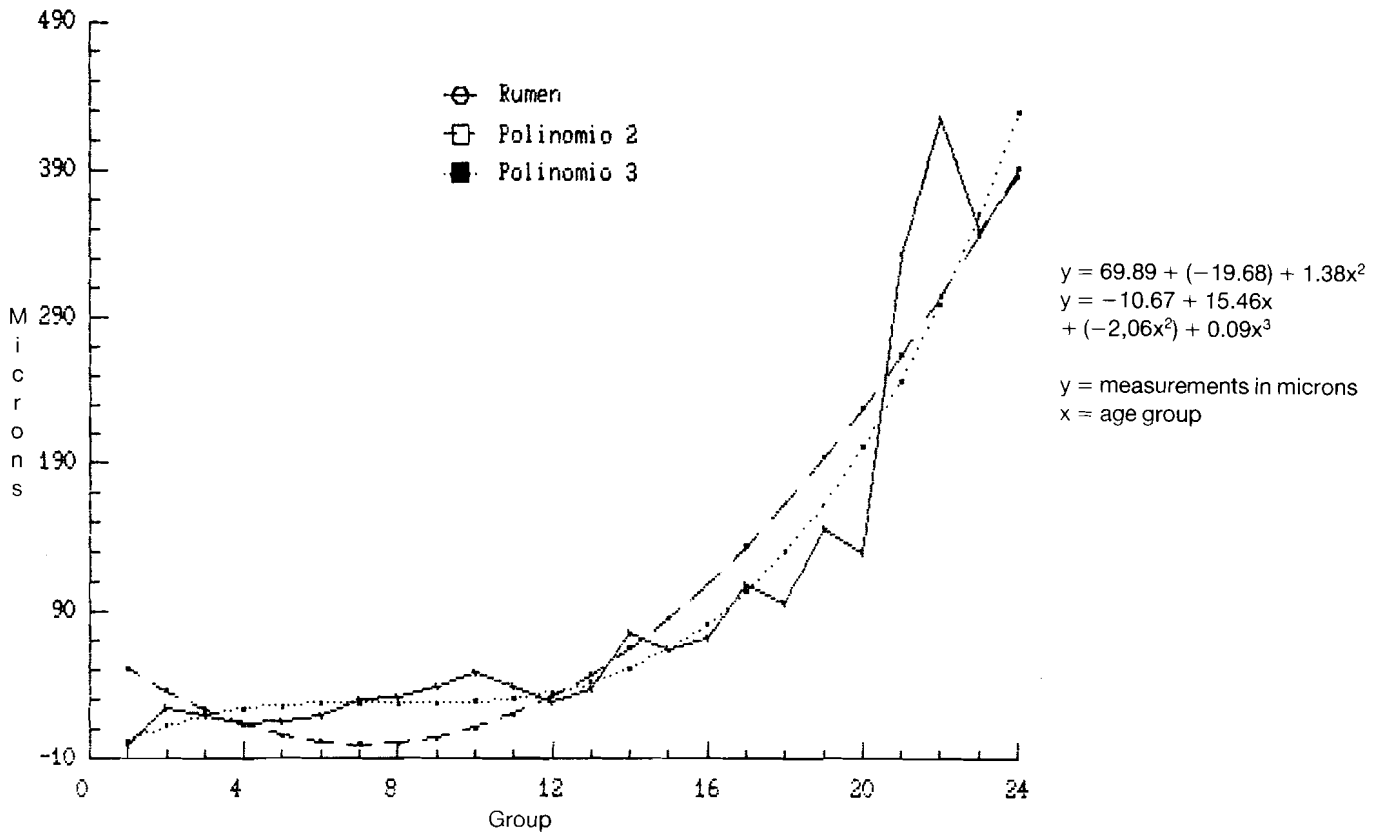
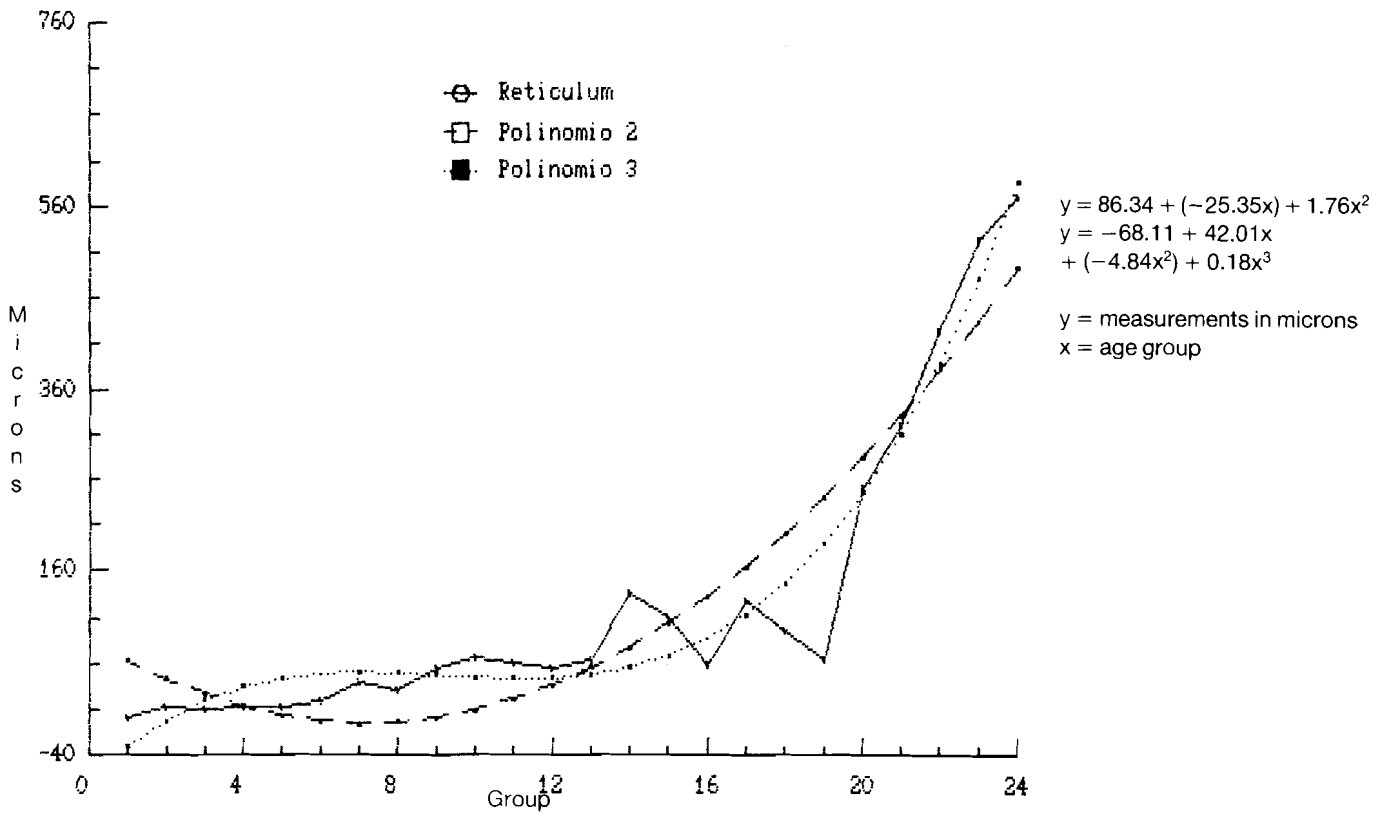


Chart 2. Model of reticulum growth



Evolution of bovine gastric compartments

Chart 3. Model of omasum growth

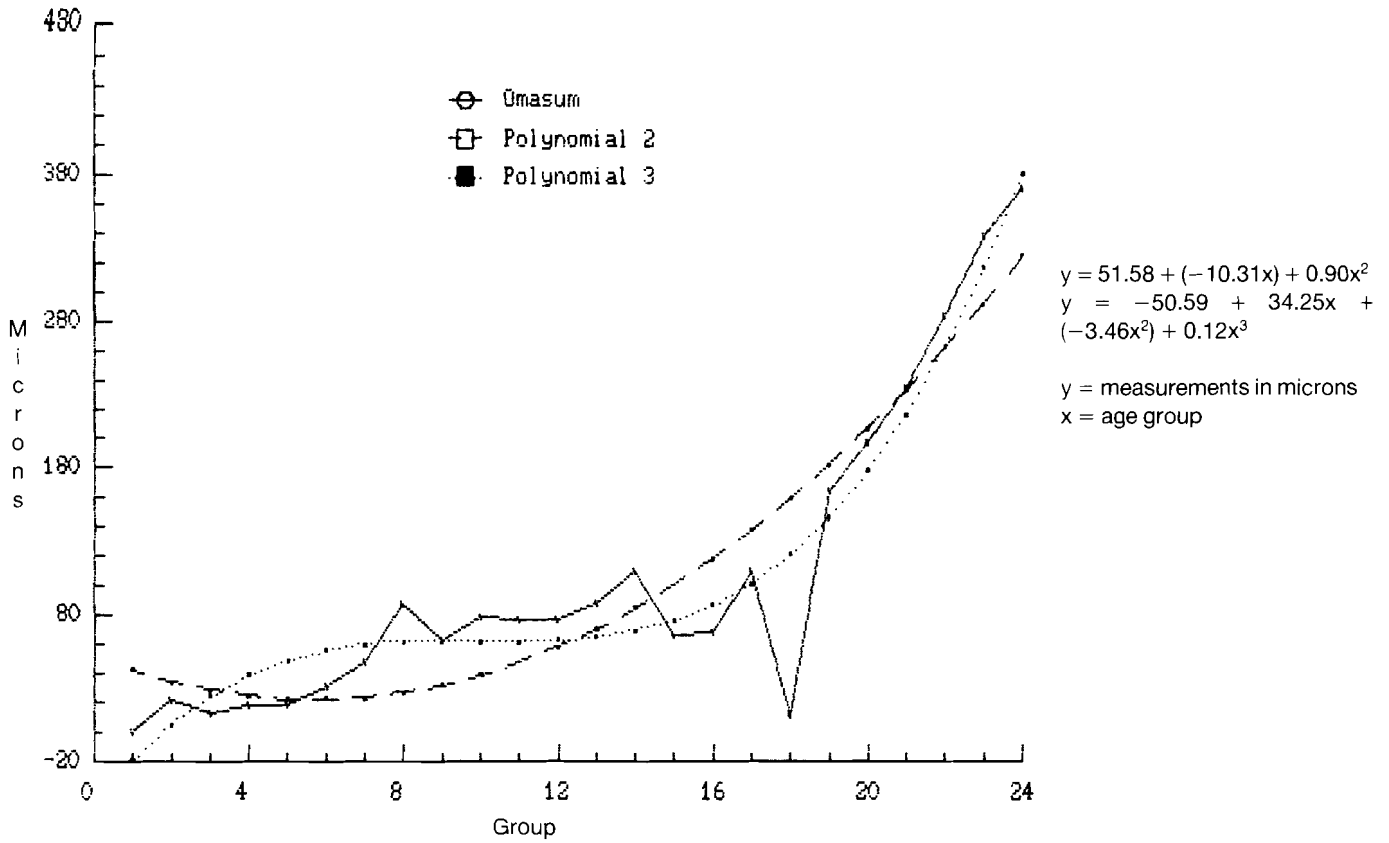
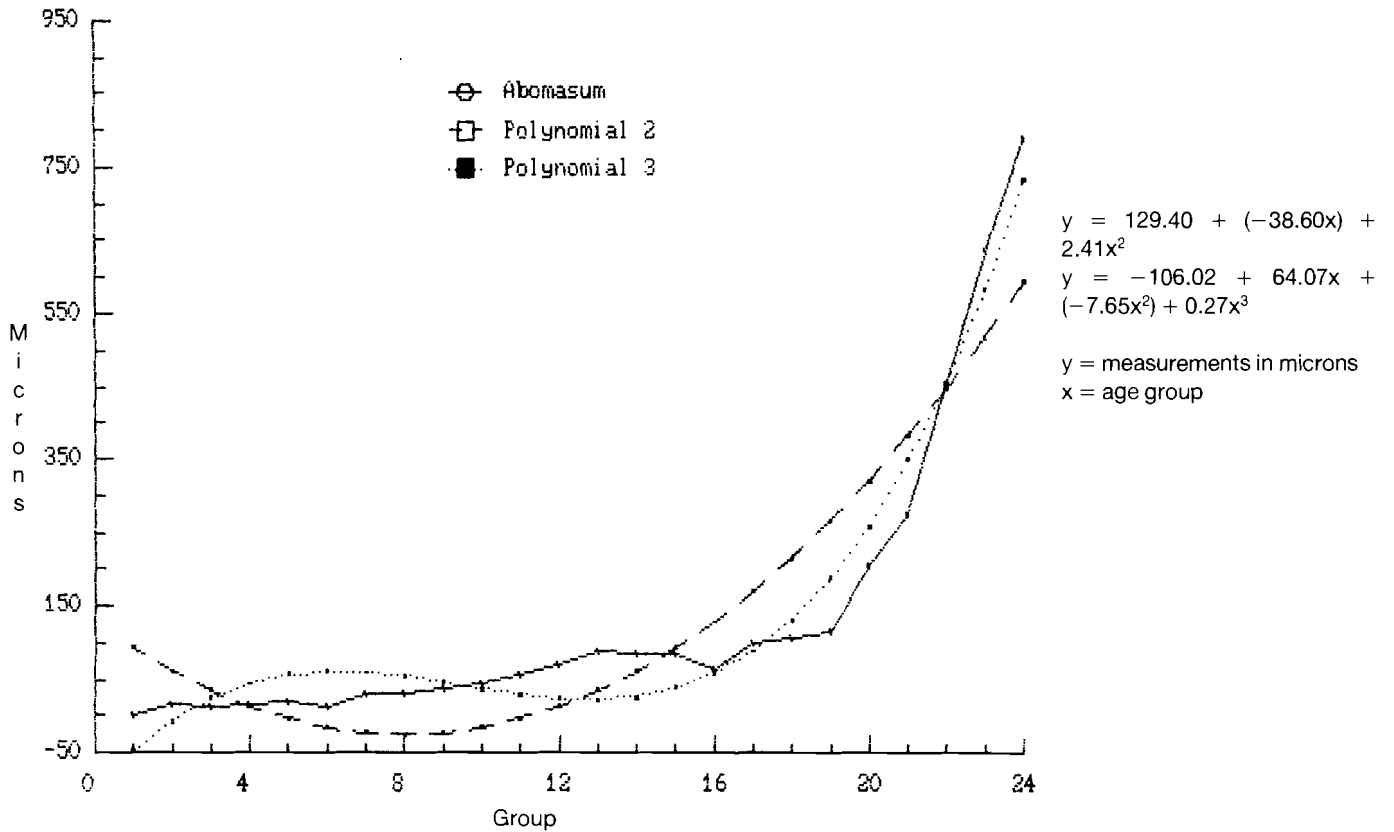
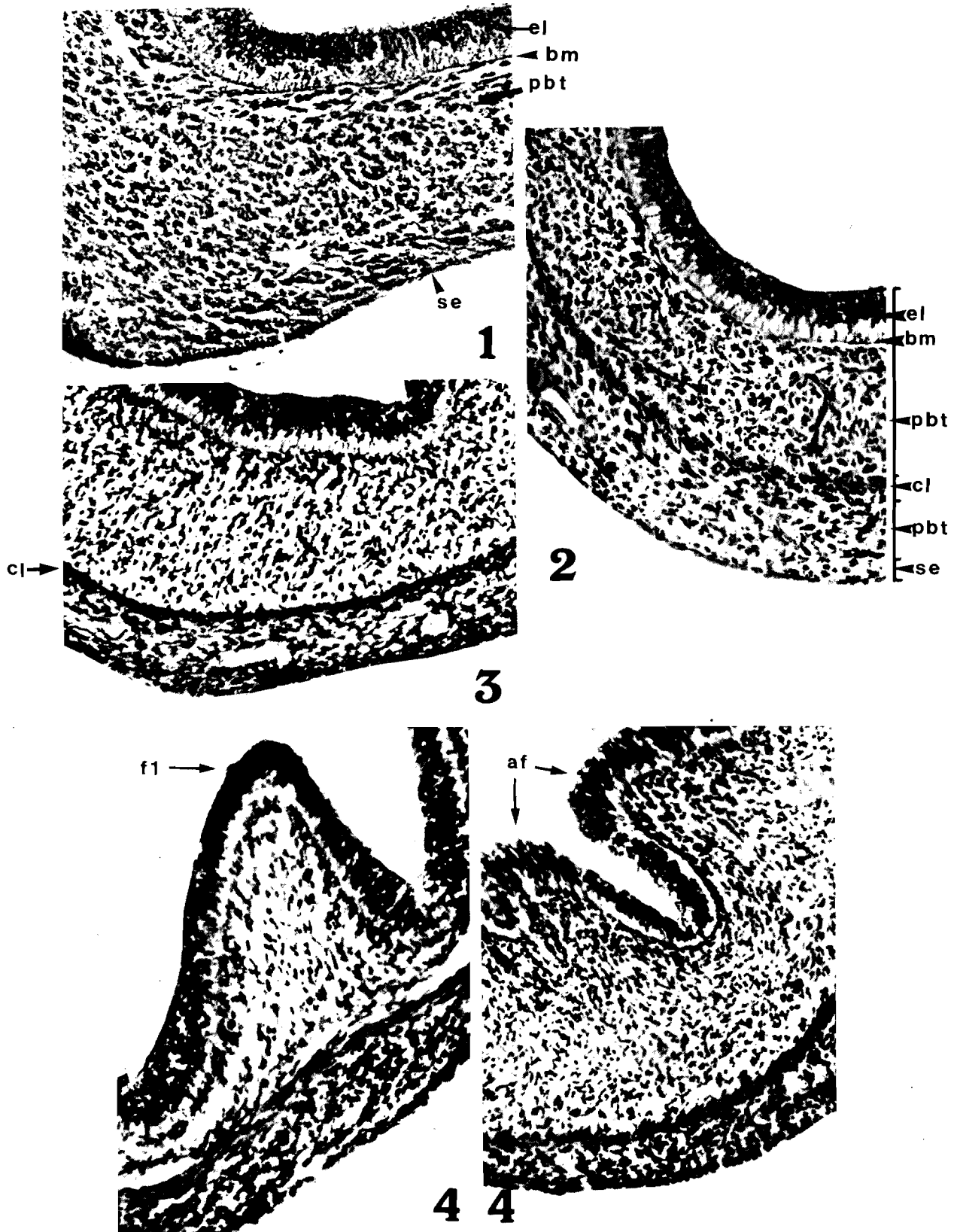


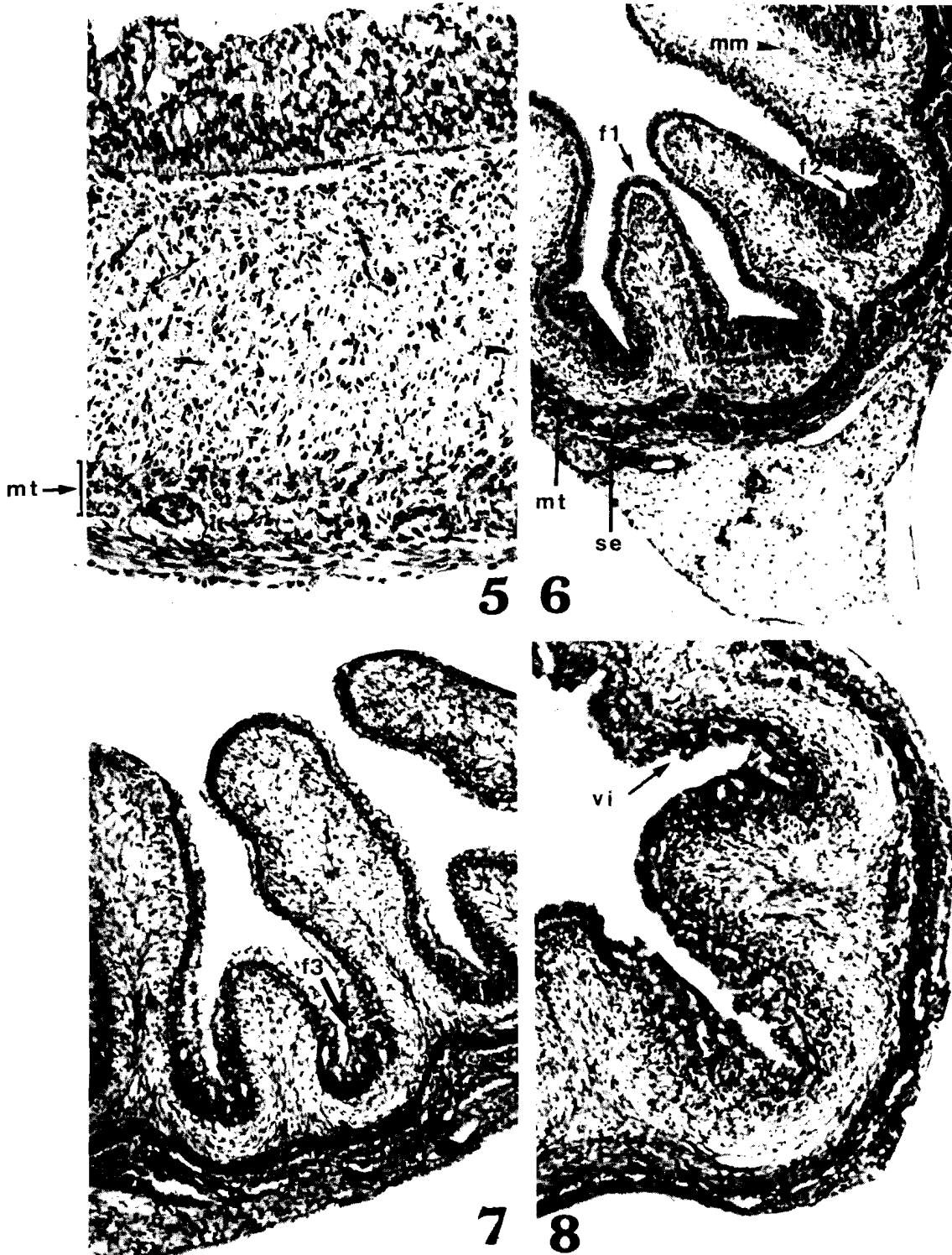
Chart 4. Model of abomasum growth





Figs. 1 to 4. Photographic composition showing different histological aspects of gastric compartments. 1 Rumen, 23 days of gestation, C-R 1.3 cm. 2 Reticulum, 30 days, C-R 1.7 cm. 3 Rumen, 36-38 days, C-R 2.2 and 2.5 cm. $\times 420$. 4 Omasum and abomasum, 40-42 days, C-R 3 and 3.3 cm. $\times 340$.

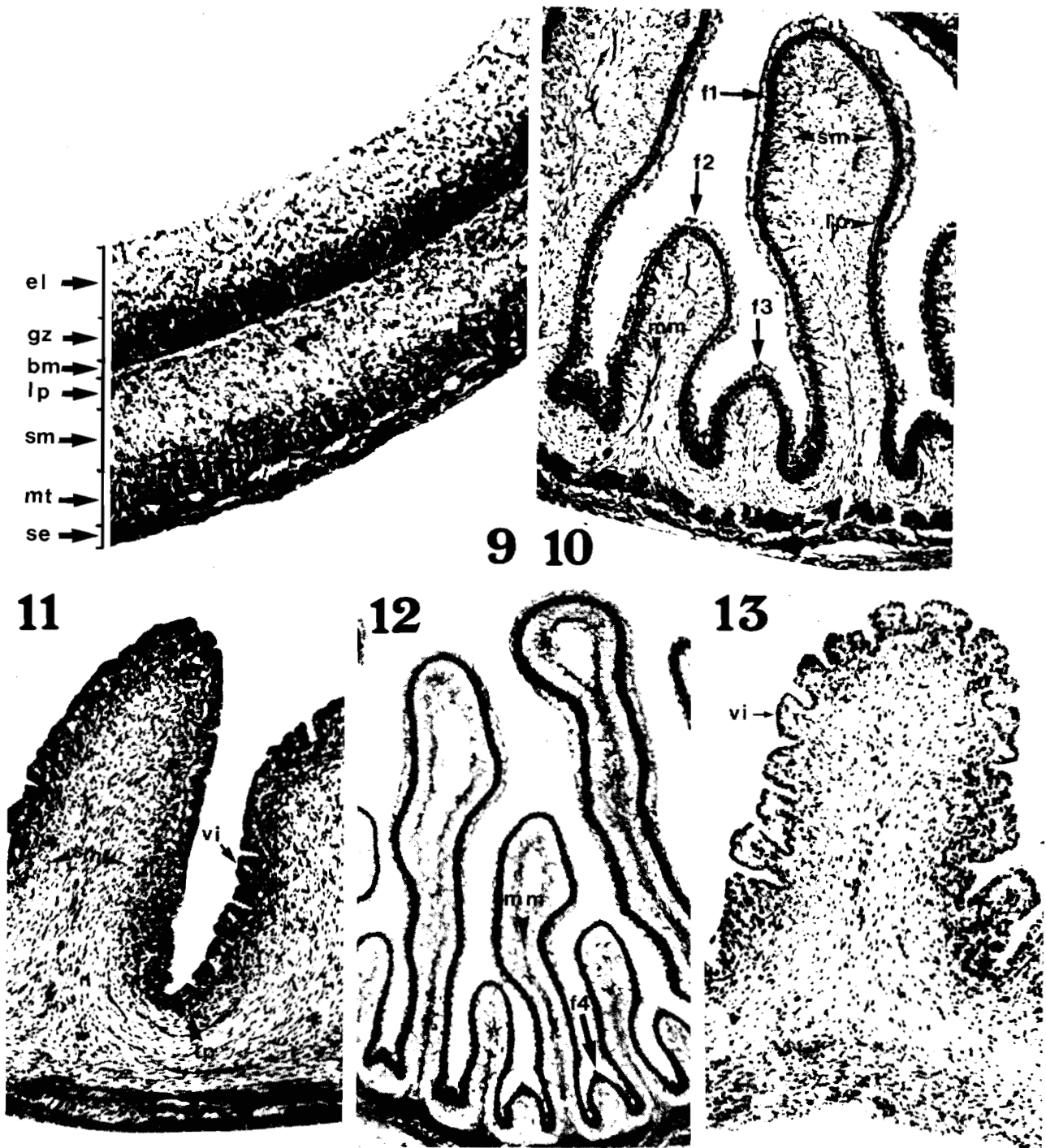
Evolution of bovine gastric compartments



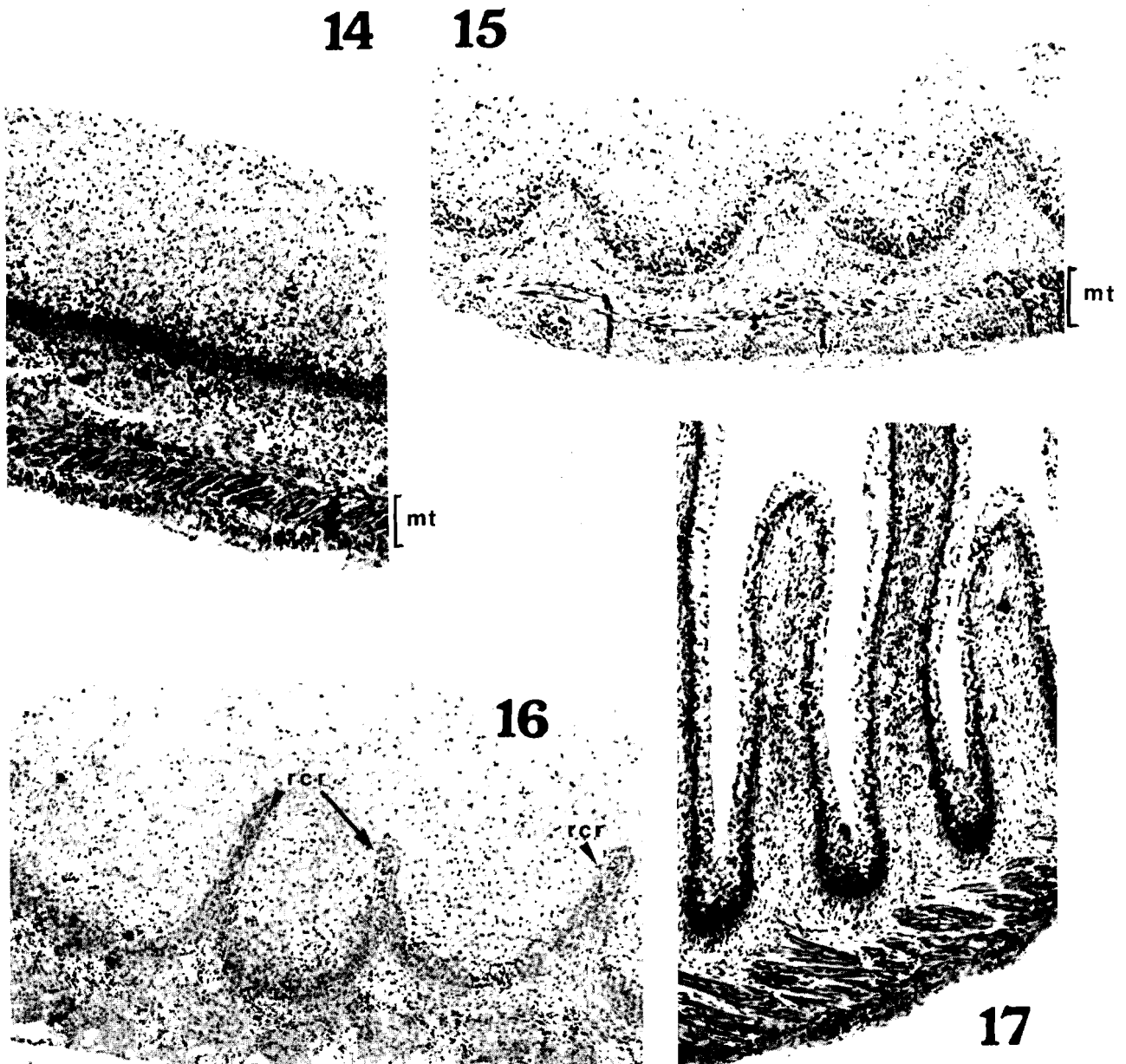
Figs. 5 to 8. Photographic composition showing different histological aspects of gastric compartments.
5 Ruminoreticular block, 44-48 days of gestation, C-R 4.2-4.7 cm. \times 420.
6 Omasum, 44-48 days, C-R 4.2-4.7 cm. \times 220.
7 Omasum, 52-57 days, C-R 5.5-6.5 cm. \times 340.
8 Abomasum, 52-57 days, C-R 5.5-6.5 cm. \times 340.

List of abbreviations

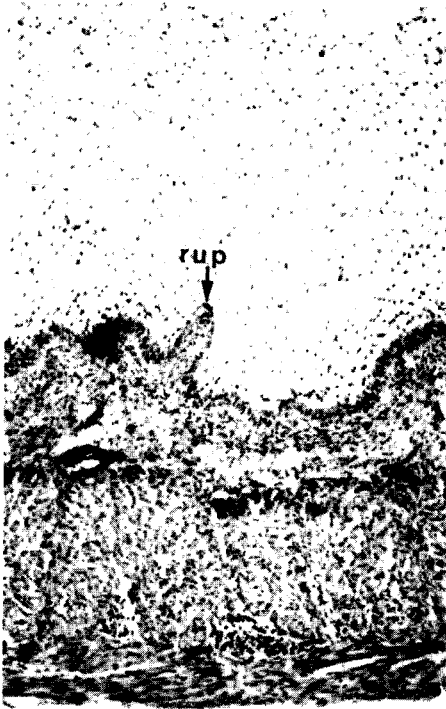
- | | |
|-----------------------------------------|-------------------------------------------|
| ab: abomasal folds | mt: muscular tunic |
| bm: basal membrane | op: omasal papillae |
| cl: cellular layer | pbt: pluripotential blastic tissue |
| f1: primary folds | rc: reticular cells |
| f2: secondary folds | rcr: reticular crest |
| f3: tertiary folds | rp: reticular corneus papillae |
| f4: quaternary folds | rup: ruminal papillae |
| gz: germinal zone | se: serosa |
| lp: lamina propria | sm: submucosa |
| mm: muscular layer of the mucosa | |




Figs. 9 to 13. Photographic composition showing different histological aspects of gastric compartments. **9** Ruminoreticular block, 60-62-64 days of gestation, C-R 7-7.5-7.8 cm. \times 420. **10** Omasum, 60-62-64 days, C-R 7-7.5-7.8 cm. \times 220. **11** Abomasum, 60-62-64 days, C-R 7-7.5-7.8 cm. \times 340. **12** \times 340: Omasum, 70-78 days, C-R 9.5-11.5 cm. \times 340. **13** Abomasum, 70-78 days, C-R 9.5-11.5 cm. \times 220.

Evolution of bovine gastric compartments

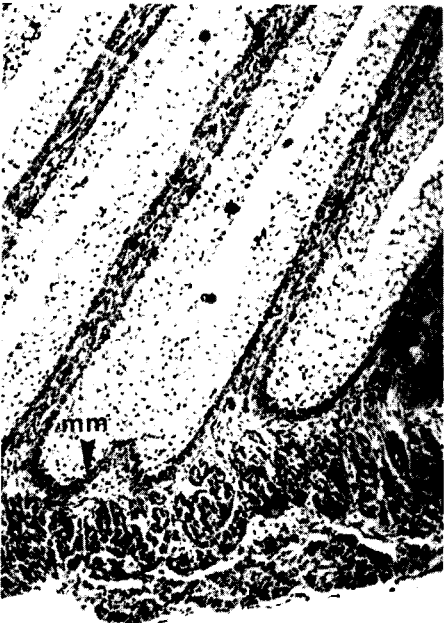
Figs. 14 to 17. Photographic composition showing different histological aspects of gastric compartments. **14** Rumen, 85 days of gestation, C-R 13 cm. \times 420. **15** \times 340: Reticulum, 85 days, C-R 13 cm. \times 340. **16** Reticulum, 90-95 days, C-R 15-16.5 cm. \times 420. **17** Omasum, 90-95 dyas, C-R 15-16.5 cm. \times 340.



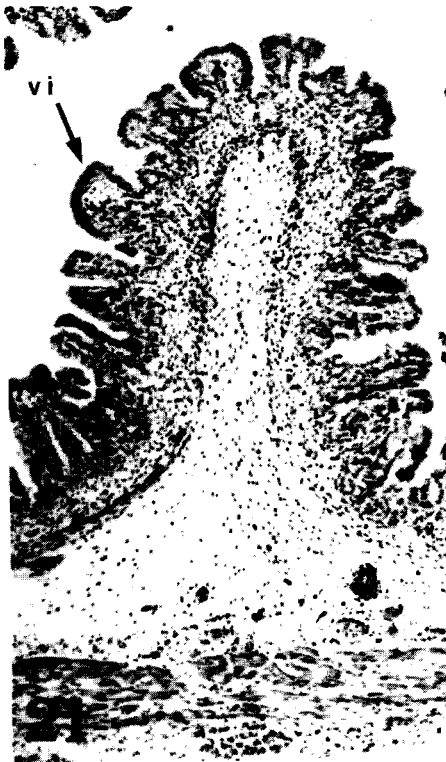18



19



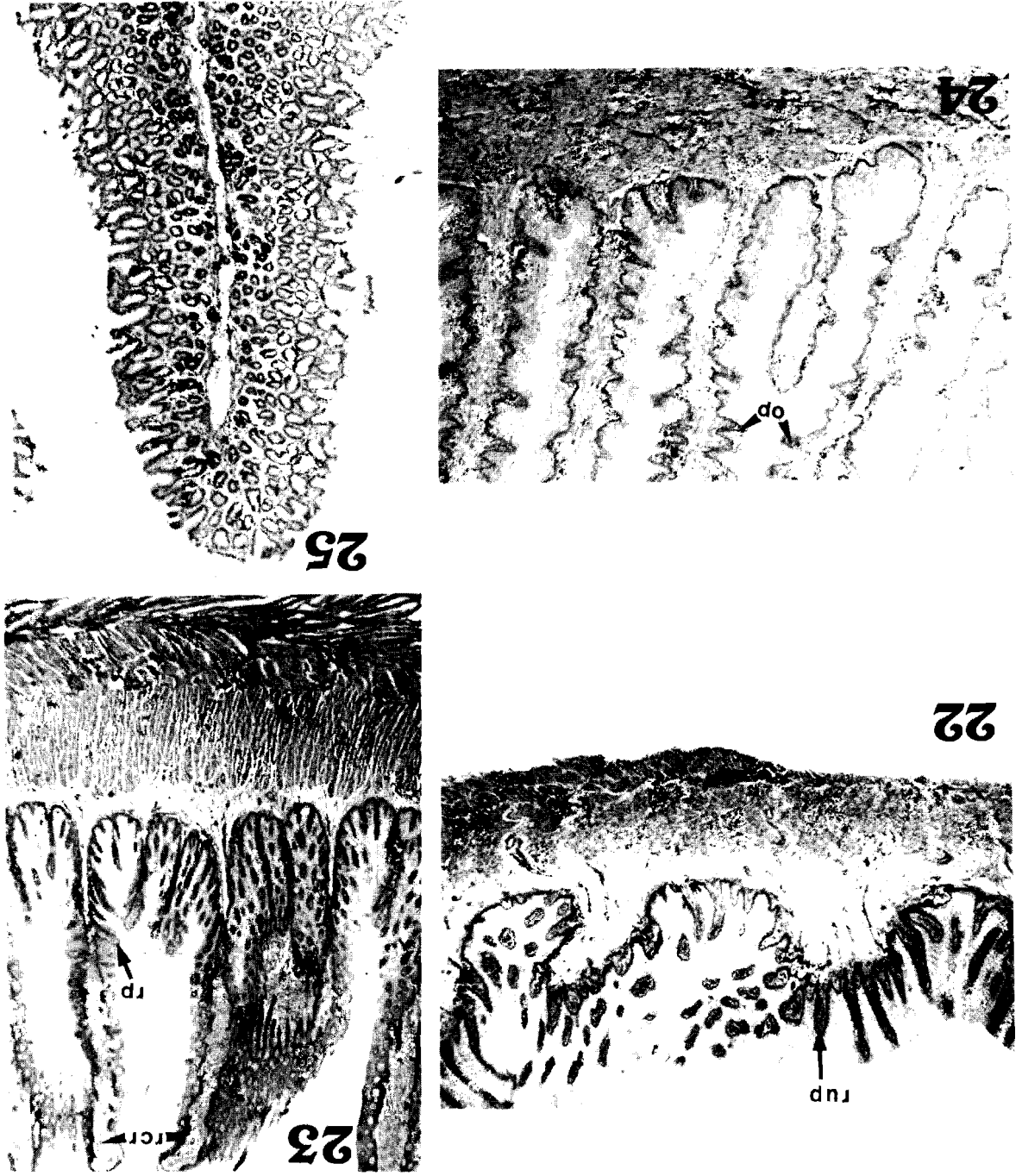
20



mt

Figs. 18 to 21.
Photographic composition showing different histological aspects of gastric compartments. 4-4.5 months of gestation, C-R 24-30 cm.
18 Rumen. $\times 220$.
19 Reticulum. $\times 220$.
20 Omasum. $\times 340$.
21 Abomasum. $\times 220$.

Evolution of bovine gastric compartments



Figs. 22 to 25. Photographic composition showing different histological aspects of gastric compartments. From 7 months to birth, C-R 62-95 cm. **22** Rumen, $\times 220$. **23** Reticulum, $\times 220$. **24** Omasum, $\times 220$. **25** Abomasum, $\times 220$.

layer, because they showed a defined tendency in their growth.

Second degree regression curves and third degree ones, together with the polynomial formulae for each compartment can be seen in charts 1 to 4.

The level of adjustment obtained was always higher in the third degree polynomial and can be considered to be quite satisfactory, because the percentage of variability that is explained by this model is 90% (Rumen); 93.2% (Reticulum); 90.4% (Omasum), and 94.86% (Abomasum).

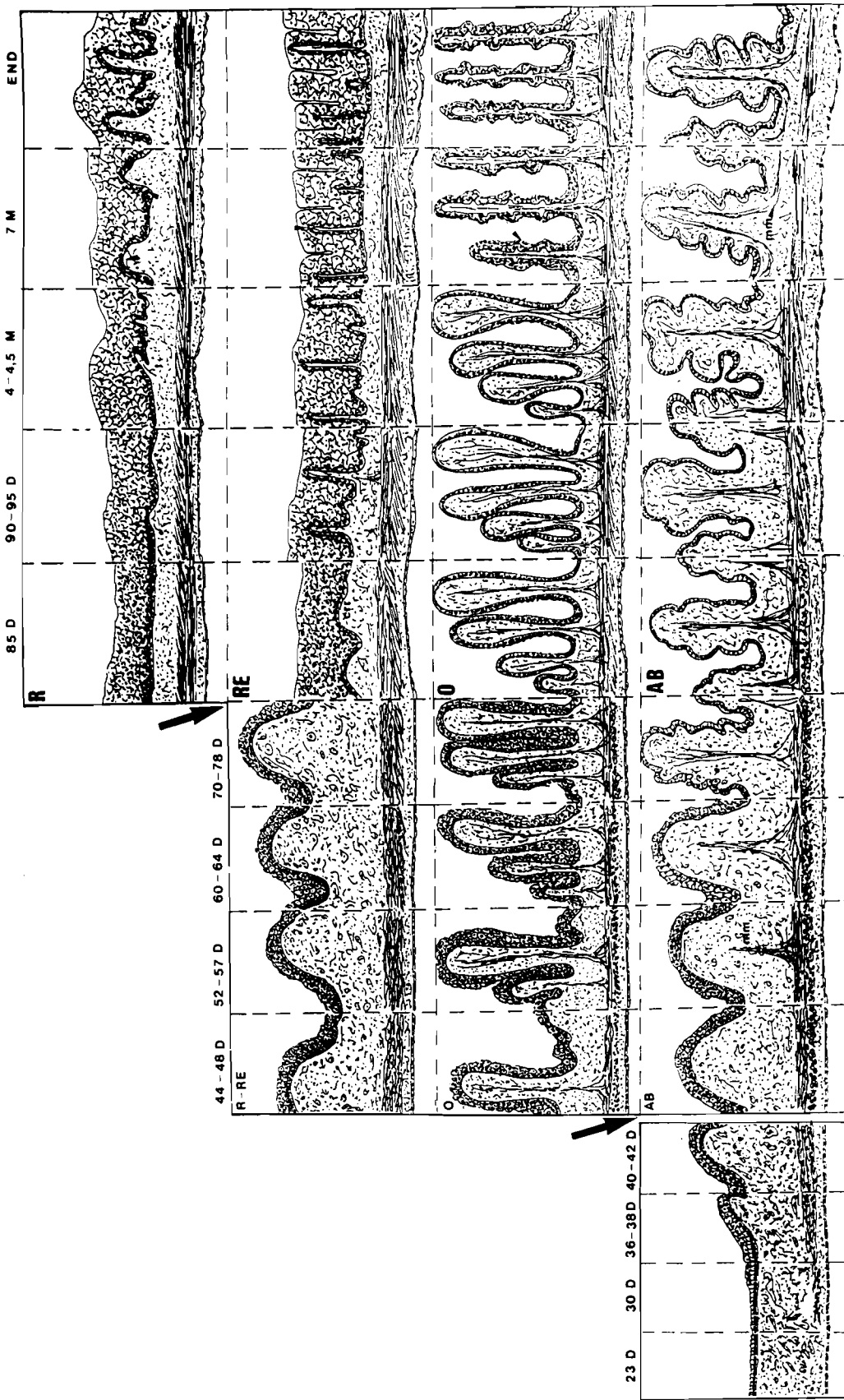
The degree of significance is $< 0.001 (***)$ in all the cases.

reticulum, because the papillae, which gave these compartments a higher degree of differentiation, took shape starting from these layers.

— The values for the epithelial lamina were high both in the rumen and in the reticulum. However, the quantities obtained for the omasum and abomasum were significantly small, which is logical since the omasal or abomasal folds have always been measured in their base,

but never as a whole.

After studying the multiple lineal regression curves applied, it was decided to choose those of the muscular



This method can be used to deduce the age of the embryos and the foetus from the measurements of the stomach muscular layer.

Discussion

The methods used to determine the age should be mentioned at this point. The Evans and Sack method (1973) was chosen from among those proposed by different authors because they managed to show quite clear tables, allowing us to accurately classify the ages (together with the development) of the specimens used in the experiment.

Some general (compartmental) aspects were drawn to our attention. In this sense, Warner (1958) maintains that the simple cylindrical epithelium appears in the bovine abomasum at C-R 7.7 cm, whereas our data placed this significant fact at C-R 10.15 cm, which coincides with the proposal concerning the buffalo given by Panchamukhi et al. (1977).

Sengar and Singh (1969) describe the ruminal papillae in the buffalo from the 8th month of gestation, while Arias et al. (1978) and Kano et al. (1981) study the papillae of the bovine rumen from the 5th month of development. Our data situated them at C-R 30 cm (135 days).

On the other hand, Panchamukhi et al. (1977) show that the nuclei of the epithelial lamina are

Macro-scheme.

Image where the different parietal changes of the developing stomach can be observed in a diagrammatic way.

distributed all over the superficial zone (apical) and medial zone of the stratum at 1.4 cm in the buffalo. Our data for bovines at C-R 1.3 cm located them in the deep (basal) and medial zone; our data did not detect the nuclei at apical and medial levels until 1.7 cm. On the other hand, the study by Warner (1958) on the bovine embryo points out a steady nuclear distribution at C-R 2 cm, and one from 2.5 cm which is similar to that obtained from our data for 1.7 cm.

The details of histodifferentiation concerning the reticulum and omasum coincided to a great extent with those put forward by other authors.

To justify the data collected in our study the histogenesis of the muscular layer must be referred to specifically. This layer was formed by two strata in adults, an outer longitudinal one, and an inner circular one, although the latter had an oblique component in the rumen and reticulum. In relation to this, the fact that the inner stratum cannot be exhaustively reflected in our results should be emphasized since we limited ourselves to specific levels, and the layout of oblique and circular fibres varied depending on the rumino-reticular level. It is also interesting to mention the contribution of Panchamukli et al. (1977) because he contends that the circular stratum appears (and he defined it) at C-R 1.5 cm and the longitudinal one at C-R 3.2 cm in the buffalo. Although this appearance may occur very early, we first detected it in the bovine omasum at C-R 4.2 cm, and before this, we could only refer to a myoblastic cellular layer.

The aspects to be discussed regarding the morphometry of the organic parietal histodifferentiation are almost non-existent, because no continual quantitative mention of the growing gastric layers could be found in the bibliography reviewed.

References

- Arias J.L., Fernández M.S. and Cabrera R. (1976). Cambios ultraestructurales en el desarrollo del epitelio ruminal del bovino. Arch. Biol. Exper. Med. 11, R3.
- Arias J.L., Cabrera R. and Valencia A. (1978). Observations on the histological development of the bovine rumen papillae. Morphological changes due to age. Anat. Histol. Embriol. 7, 140-151.
- Arias J.L., Fernández M.S. and Cabrera R. (1979). Distribution and nature of desmosomes in the bovine developing ruminal epithelium. Acta. Anat. 105, 309-313.
- Birgele E.L. (1969). Histogenesis and histochemical properties of the mucoid cells abomasum fundal mucosa. Izu. Akad. Nauk. Latv. Ssr. 4, 137-139.
- Birgele E.L. (1969). Differentiation of the accessory cells of the abomasum mucosa fundic glands in the development of cattle. Izu. Akad. Nank. Latv. Ssr. 6, 127-129.
- Evans H.E. and Sack W.O. (1973). Prenatal development of domestic and laboratory mammals. Growth curves, external features and selected references. Anat. Histol. Embryol. 2, 11-45.
- Kano Y., Fukaya K., Asari M. and Eguchi Y. (1981). Studies on the development of the fetal and neonatal bovine stomach. Zbl. Vet. Med. C. Anat. Histol. Embryol. 10, 264-274.
- Kurnosov K.M., Danilova L.V. and Gurova N.I. (1960). The external appearance of the embryo and fetus of the cow. Trudy Inst. Morfol. Zhivot. 29, 103-109.
- Lambert P.S. (1948). The development of the stomach in the ruminant. Brit. Vet. J. 102, 302-310.
- Molinari E. and Jorquera B. (1988). Periodos del desarrollo intrauterino de los compartimentos gástricos del caprino (*Capra hircus*). Zbl. Vet. Med. C. Anat. Histol. Embryol. 17, 121-137.
- Nichols C.W. Jr. (1944). The embryology of the calf. Fetal growth weights, relative age and certain body measurements. Am. J. Vet. Res. 5, 135-141.
- Panchamukhi B.G. (1981). Stomach content in prenatal development of buffalo stomach. Ind. J. Anim. Sci. 58, 832-833.
- Panchamukhi B.G., Mudolkar D.R. and Srivastava H.C. (1977). Prenatal development of the buffalo (*Bubalus bubalis*) stomach. 3. Early histogenesis. Ind. J. Anim. Sci., 47, 463-469.
- Panchamukhi B.G. and Mudholkar D.R. (1978). A note on cornification in the prenatal forestomachs of the buffalo (*Bubalus bubalis*). Ind. J. Anim. Sci. 48, 473-476.
- Panchamukhi B.G. and Srivastava H.C. (1979). Histogenesis of the rumen of the buffalo (*Bubalus buvalis*) stomach. Anat. Histol. Embryol. 8, 97-105.
- Panchamukhi B.G. and Srivastava H.C. (1980). Histogenesis of the reticulum of the buffalo (*Bubalus bubalis*) stomach. Ind. J. Anim. Sci. 60, 1064-1070.
- Panchamukhi B.G. and Srivastava H.C. (1982). Histogenesis of the reticular groove of the buffalo (*Bubalus buvalis*) stomach. Am. J. Vet. Res. 43, 346-349.
- Postma C. (1947). Determination of age in the bovine fetus. Tijdschr. Diergeneesk. 72, 463-531.
- Sengar O.P.S. and Singh S.N. (1969). Studies of the digestive system of ruminants. Part I: Development of fore-gut and compound stomach in Buffalo - *Bos bubalis* L. Agra. Univ. J. Res. Vol. XVIII Pt. III.
- Sengar O.P.S. and Singh S.N. (1970). Studies on the digestive system of ruminants. Part IV: Structure of the compound stomach in Buffalo. *Bos bubalis* L. Agra. Univ. J. Res. Vol. XIX. Pt. II.
- Thomsen J.L. (1975). Body length, head circumference, and weight of bovine fetuses. Prediction of gestational age. J. Dairy Sci. 58, 1370-1373.
- Vivo J.M. (1987). El desarrollo del estómago del vacuno frisón: análisis desde el prisma morfológico y morfométrico. Thes. Doct. Fac. Vet. Univ. Extr. Cáceres.
- Warner E.D. (1958). The organogenesis and early histogenesis of the bovine stomach. Am. J. Anat. 102, 33-63.